TREATMENT OF THE MALIGNANT TUMORS OF THE ORAL CAVITY AND THE OROPHARYNX WITH MICROSURGICAL RECONSTRUCTIVE METHODS

Doctoral dissertation

Ferenc Oberna MD DMD

Oral and Maxillofacial Surgery Dept. of St. Rókus, Budapest
Oral Maxillofacial Surgery and Oto-rhino-laryngology Dept.
of County Hospital of Bács-Kiskun, Kecskemét

Supervisor: György Szabó MD. DSC

Semmelweis University PhD School of Clinical Medical Sciences,
Dental sciences resarch program
Vezető: Dr. Varga Gábor egyetemi tanár az MTA doktora

Budapest
2008

I. INTRODUCTION

90% of the malignancies of the oral cavity and oropharynx are squamous cell carcinoma, with an international and local incidence rate ranking it the 6th most common malignant tumor. According to Central Statistics Bureau (KSH) data from 1998-2003, it is the 3rd most common tumor mortality in men and 14th most common in women, with a 45% yearly mortality of the registered patients resulting in an average 1600 deaths yearly. The occurrence has increased six fold in the last 20 years, surpassing the rate of increase of other malignancies. The total number of malignant tumors has been stagnating in Hungary since 2000, but the general European tendency of a 6% decrease has unfortunately not been recoded in this tumor localization.

Although tumors of the oral cavity are readily accessible due to their anatomic location, most are diagnosed at an advanced stage. The treatment consists of complex oncotherapy, the basis of which to the present day is the radical surgical procedure. In the malignancies of the oropharynx, this is usually performed secondarily, in the treatment of residual tumor or as a salvage procedure. As the propagation of the tumors of the oral cavity toward the oropharynx have no actual barrier, surgical treatment usually involves both regions. Surgical excision of the primary tumor and the regional lymph nodes greatly influences the feeding and speech functions, as well as the appearance of the patient due to the amount of excised tissue.

In patients receiving complex oncotherapy for oral cavity tumors, especially in the case of composite surgery, the accepted method for large surface area and tissue volume replacement is the microsurgical free tissue transfer. I have chosen as my thesis reconstructive microsurgery and it’s application in the complex therapy of tumors of the oral cavity and oropharynx, along with the analysis of the oncological and quality of life results, in order to be able to analyze on my own group of patients the various treatment modalities of this tumor type which is causing such a serious public health problem.

II. OBJECTIVES

1. The analysis of the criteria necessary for routine use of free tissue transfer in the field of head, neck, and the oral cavity.

2. The evaluation of the surgical success rate of free tissue transfer, and analysis of the reasons for flap failure. The assessment of acute and early perioperative surgical complications.

3. Flap salvage in acute circulation disorders, and the examination of different alternatives for tissue replacement.

4. Assessment of the success rate of free tissue transfer and surgical complication in patients receiving preoperative radiation therapy.

5. Analysis of the survival rates and prognostic factors for patients receiving surgical treatment (with/without adjuvant vs. neoadjuvant radiotherapy, or chemotherapy) and the comparison of this data to those found in literature.

6. The assessment of the quality of life in recurrence free patients receiving surgical treatment with microsurgical reconstruction for tumor of the oral cavity and the oropharynx. The comparison of these results with radiation treatment alone (external beam and brachytherapy) with an aim to retain function in tongue base carcinoma.

III. PATIENTS AND METHODS

We started an investigation in 2003 at the St. Rókus Hospital Department of Oral- and Maxillofacial Surgery to assess the results of microsurgical free tissue transfer carried out mainly for tumor of the oral cavity, facial and mandibular regions. The scope of the investigation was extended to the Bács-Kiskun County Hospital, Veszprém County Cholnoky Ferenc Hospital, the Dél-pesti Jahn Ferenc Hospital and the Uzsoki street Hospital in Budapest, the National Institute of Oncology and the National Institute of Neurosurgery, where we carried out similar operations for similar indications in the capacity of consulting surgeons.

Free tissue transfer in the oral cavity, oropharynx, facial and mandibular regions

Patients: We performed 151 microsurgical reconstructive procedures on 142 patients on the facial, mandibular, oral cavity and oropharyngeal regions between August 10,

2003 and July 1, 2008. We examined the reliability of the surgical method on this patient group, the success rate and the complications related to the procedures.
87% of the free tissue transfers were performed due to tumor (table 1.)

TABLE 1: Indications for free tissue transfer

Malignant tumors of the oral cavity		***130***
	Epidermoid carcinoma	*126*
	Mucoepidermoid cc	*1*
	Primitive neuroectodermal tumor (PNET)	*1*
	Osteosarcoma	*2*
Skin tumors or tumors ulerating the skin		***3***
	Skin tumor with bone propagationt	*1*
	Skin propagation of parotid tumor	*1*
	Intracranialis meningeoma	*1*
Inflammation,,degenerative bone disease		***4***
	Sequestrating chronic osteomyelitis	*1*
	Osteoradionecrosis	*2*
	Bisphosphonate induced osteonecrosis	*1*
Benign tumors of the oral cavity		***2***
	Keratocyst	*2*
Developmental Malformitiesk		***3***
	Malformation of the jawr	*1*
	Cheilognathopalatoschisis	*2*
Flap necrosis, postoperative complications		***9***
	Second flap due to flap necrosis	*8*
	Postoperative necrosis of the skin of the neck	*1*
Total:		***151***

Microsurgical Tissue replacement methods

Depending on the quality of tissue in the area of replacement, soft tissue and composite bone free tissue flaps were used (Table 2.). In order to reduce procedure time, flaps that could be harvested under bloodless conditions parallel to the oncological resection were primarily used. Microsurgical anastomoses were performed using a surgical loupe (Heine 2.5X magnification, with a working distance between 320-420 mm) sutured with 8/0 or 9/0 monofil surgical sutures.

TABLE 2: The types of free flaps and frequency of their use

Soft tissue replacement	Serratus anterior musculocutaneous flap (SAMCF)		*1*
	Serratus anterior muscle flap (SAMF)		***2***
	Lateral arm flap(LAF)		***3***
	Latissimus dorsi musculocutaneous free flap (LD)		***12***
	Radial forearm flap (RFF)		***119***
		Fasciocutaneous (FC)	*117*
		FC nerve	*1*
		FC+ tendon	*1*
Bone (soft tissue)replacement	Fibular flap (FF)		***12***
		Bone flap	*8*
		Bone + cutaneous flap	*4*
	Radial forearm flap with radial bone segment (RFOFCF)		***2***
Total			***151***

A./ Soft tissue replacement using microsurgical methods

Radial Forearm Flap: Our fist choice is the radial forearm fasciocutaneous flap in the oral cavity where large areas need soft tissue replacement. Preoperatively we examine the circulation of the non-dominant hand with clinical trials (Allan test) and Doppler when necessary, because the radial artery is removed with the flap. We check the arterial circulation of the flap intra operatively as well. We prepare the double (superficial and deep) venous outflow flap under bloodless conditions (250-280mmHg pressure) according to the operative plan, centered on the cephalic vein. We test intraoperatively the circulation of the superficial vein which are simpler to suture by temporarily clamping the deep veins. We place a circular suture around the donor site in order to narrow the defect, with an effort to cover the tendon of the flexor carpi radialis muscle. We harvest the split thickness skin graft using a dermatome from the lateral surface of the thigh. After dressing the wound, we use ACE wrap without splinting.

Latissimus dorsi musculocutaneous flap

Generally used as a second, salvage flap in the soft tissue replacement of the oral cavity. It is indicated for use as a primary flap in large area and volume

replacements, typically seen in total tongue excision or two layer tissue replacements. Preoperative angiography is not necessary to design the flap. The skin pedicle is planned in the central area containing the majority of musculocutaneous perforators, with the long axis parallel to the direction of the ribs in order to facilitate harvest area closure. The flap can be harvested as a perforator flap when there is no need for extra soft tissue volume, in order to reduce donor site morbidity by minimizing the amount of excised muscle.

Other flaps

Occasionally various other flaps were used for soft tissue replacement (lateral arm flap, serratus anterior muscle or musculocutaneous flap) due to their advantageous properties or when the conventionally used free flaps were not available.

B./ Replacement of hard tissue-, mandible replacement with microsurgical methods

In case of patients with oral cavity or oropharynx tumors the partial defects of the maxilla were replaced with free soft tissue transfer or prosthesis obturator. We used two methods for replacement of segmental discontinuities of the mandible.

Alloplastic replacement and microsurgical soft tissue flap

Definitive replacement of the mandible is not performed at the time of mandible resection due to the expected poor prognosis. The segmental mandible defect is bridged with a reconstructive plate (Leibinger Recon 2.3mm). In order to prevent postoperative wound dehiscence the soft tissue defect is covered by a microsurgical flap.

Fibula osteo(musculo-septocutaneous) free flap

An ideal method for large mandible defect or bone replacement following irradiation. The well planned skin pedicle has a reliable circulation, the harvested bone and muscle can replace the oral cavity floor defect. In our practice it can be used primarily for tissue replacement in benign cases, and in the defects if the anterior segment of the mandible in malignant tumors. Other localizations in oncologic surgery allow the flap to be used for secondary reconstruction following plate fixation of mandibular defects. Preoperative evaluation of the lower leg is performed with CT, MRI or DS Angiography.

The fibular flap is harvested under bloodless conditions (350mmHg) from a lateral approach in a distal to proximal direction. The proximal and distal 6-8 cm long fibula segments are spared. The skin paddle is planned on the border of the middle and lower thirds, and the perforators are identified intraoperatively. The bone flap, which is designed on the peroneal artery and vein, is designed to fit the recipient area after deflation of the compression cuff with the circulation still intact, based on previous measurements or templates. The corpus of the mandible is formed by cutting out wedge shaped segments, while the angulus is formed by performing longitudinal, axial osteotomy, after which the segments are fixed with mini-plates. The donor site defect is closed primarily or with split thickness skin graft, the wound is dressed and ACE wrapped. The patients are mobilized from day 3.

Patients with intraoral squamous cell carcinoma or oral cavity-oropharyngeal propagation

Patients, method: 100 of the 142 patients receiving microsurgical free tissue transfer between August 10, 2003 and May 31, 2007 had mostly advanced (stage III. and IV.) oral cavity, oropharynx propagating squamous cell carcinoma and were treated along uniform oncologic principles of radical or salvage operation with or without radio(chemo) therapy. (Table 3 and 4).

TABLE 3: Pre and postoperative treatment modalities (for patients undergoing surgery)

Preoperative trreatment of recurrent tumor	*Total*	***20 (20%)***
	Surgery	*3*
	Surgery and postoperative irradiation	*3*
	External beam irradiation	*12*
	Chemoradiotherapy	*2*
Primary surgery postoperative treatment:	*Total*	*75 (94%)*
	External beam radiotherapy (less than 60Gy)	*64*
	External beam radiotherapy (more than 60Gy)	*4*
	Chemoradiotherapy treatment	*6*
	Interstitial radiotherapy (HDR BT)	*1*
Other	External beam radiotherapy suspended	*1*
	Postoperative treatment - unknown	*2*

TABLE 4. The characteristics of the oncologic patient group (patient characteristics)

		Primaryr	***Salvage***
Age years (average, range)		53.7 (26-75)	56 (42-75)
Sex	Male	59 (73.8%)	14 (70%)
	Female	21 (26.2%)	6 (30%)
T stage	T1	1 (1.3%)	0 (0%)
	T2	13 (16.3%)	2 (10%)
	T3	10 (12.5%)	2 (10%)
	T4	56 (70.0%)	16 (80%)
N stage	N0	35 (43.8%)	14 (70%)
	N1	30 (37.5%)	1 (5%)
	N2a	1 (1.3%)	1 (5%)
	N2b	12 (15.0%)	2 (10%)
	N2c	2 (2.5%)	2 (10%)
pT stage	T1	12 (15.0%)	1 (5%)
	T2	14 (17.5%)	3 (15%)
	T3	10 (12.5%)	3 (15%)
	T4	44 (55.0%)	13 (65%)
pN stage	N0	33 (41.3%)	14 (70%)
	N1	15 (18.8%)	3 (15%)
	N2a	0 (0%)	1 (5%)
	N2b	22 (27.5%)	1 (5%)
	N2c	10 (12.5%)	1 (5%)
ST	I	1 (1.3%)	0 (0%)
	II	7 (8.8%)	2 (10%)
	III	14 (17.5%)	2 (10%)
	IV	58 (72.5%)	16 (80%)
pst	I	8 (10.0%)	1 (5%)
	II	5 (6.3%)	2 (10%)
	III	15 (18.8%)	4 (20%)
	IV	52 (65.0%)	13 (65%)
Grade	I	14 (17.5%)	2 (10%)
	II	59 (73.8%)	17 (85%)
	III	7 (8.8%)	1 (5%)

Quality of life analysis

Patients: In the period between August 10, 2003 and May 31, 2007, 50 patients, who were operated and received adjuvant therapy in the Szent Rókus Hospital, and 22 patients receiving external beam radiation and boost HDR interstitial therapy alone as a protocol for advanced tongue base tumor, with a 1 year survival were examined for pre and postoperative head and neck specific quality of life status, and their results were compared.

Quality of life analysis method: Quality of life assessment was made using the Hungarian translation of the head-neck patients' functional questionnaire published by List, supplemented by a visual analogue pain scale, and further specific questions in connection with dental status, xerostomy, taste sensation, and limitation of shoulder range of motion.

Statistics

The BMDP program package (Biometrics Department, University of California, Los Angeles, USA) SOLO 3.1 version was used for statistical evaluation. The probability for survival was calculated using the Kaplan and Meier method, the Fisher-exact test compared the difference in frequency of events, and the survival differences were analyzed with the log-rank test. We analyzed with a single and multi variant Cox regression model the possible risk factors of local and locoregional tumor free status and overall survival (OS). From the regression coefficient we calculated the relative risk (RR) and the 95% confidence interval (95%CI). We considered $p \leq 0.05$ to be statistically significant.

IV. RESULTS

Free tissue transfer in the region of the oral cavity, oropharynx, and the jaw bones

The average operation time for the 151 microsurgical reconstructive procedures was 333 minutes. Aside from the nasotracheal intubation and assisted ventilation in the intensive care unit, we only had to perform tracheostomy in 8 cases (5%). Postoperative hospital days were 17.7 on average (range 7-62 days). There was one

perioperative exit of a 56 year old male (0.66%) due to malignant ventricular fibrillation on day 11. In 147 cases (91%) the microsurgical tissue transfer was carried out successfully. We observed total flap necrosis in 12 cases (8%) and partial flap necrosis in 2 cases (1%). A second free tissue transfer was necessary in 8 (5.3%) of the total flap necrosis cases. The 12 cases of total flap necrosis consisted of 2 lateral arm flaps (2/3), 2 serratus anterior muscle flaps (2/3), 8 radial forearm flaps (8/121), (Table 5.). Flap necrosis was caused in 8 cases by venous, in 3 cases by arterial and in 1 case arterial and venous thrombosis. In 10 cases thrombosis occurred in the first 48 hours, in 2 cases on postoperative day 4. Elimination of the venous blockage was unsuccessful in every case. Arterial blockage occurred on the day of the operation. In three cases when arterial blockage was detected within the first 2 postoperative hours, the circulation of the flap could be saved with only partial necrosis by performing a reanastomosis. Patients receiving free tissue transfer for benign disease had a 100% success rate (10/10). We did not observe any necrotic complications in our last 80 cases.

TABLE 5: Partial and total flap necrosis

		No. of cases	%
Flap necrosis	Total flap necrosis	12/151	8%
	Partial flap necrosis	2/151	1%
	Salvage second flap	8/151	5,3%
Total flap necrosis by flaps	Radial forearm flap	8/121	6,6%
	Lateral arm flap	2/3	
	Latissimus dorsi myocutaneous flap	0/12	0%
	Serratus anterior myocutaneous flap	2/3	
	Fibular flap	0/12	0%
Partial flap necrosis		2/151	1%
	Fibula septomyocutaneous flap	1/4	
	Latissimus dorsi myocutaneous flap	1/12	
Flap necrosis necessitating reoperation		9/151	5,9%
	Radial forearm flap	4/121	3,3%
	Lateral arm flap	2/3	
	Serratus anterior myocutaneous flap	1/3	
	Fibula septocutaneous flap	1/4	

We observed surgical complications free healing in the periorperative period in 58% of our patients. In 48% of the cases where we did see surgical complications, the most common complications were the graft take problems associated with the split thickness skin graft transplanted on the donor area of the forearm 19.8% (24/121). Second operation due to this complication, however, was rarely needed 1.6% (2/121). Reoperation was necessary in 7 cases (4.6%) due to surgical complications, in 3 cases due to postoperative bleeding, 2 cases due to exposed plates, and in 2 cases due to infection. Even though the primary tumor and the cervical metastases were excised in one block (monoblock), we found that orocutaneous fistulae seldom developed 4/148 (2,7%) as a result of intraoral wound dehiscence.

Patients with intraoral squamous cell carcinoma or oral cavity-oropharyngeal propagation

A./ Tumor resection, primary free tissue transfer, postoperative irradiation

The average follow up period of the 80 patients who received a free tissue transfer during their primary procedure with or without postoperative irradiation was 22.6 (2-59) months (SD 13.8). We did not observe any distant metastasis during the follow up period. We did not lose any patients to intercurrent disease. We observed on average the following recurrences after surgery and postoperative treatment; 10 months (1-25) 15% local recurrence, 10.4 months (4-16) 8.75% regional lymph node metastases, 10.2 months (1-25) 18.9% locoregional recurrence.

We performed salvage operation in only one case due to tumor recurrence. We did not find the other patients with recurrence suitable for salvage procedure, they received palliative chemotherapy.

We performed neck dissection in two cases based on clinical symptoms of contralateral metastases, however the histology did not confirm involvement of those nodes.

The LTC (local tumor control) calculated with the Kaplan-Meier method for 3 years was 82%, the RTC 89%, the TS and DSS (disease/tumor specific survival) ratio was 69% and 71% (diagrams 1 and.2). The DSS stage I-IV. 100%-100%-68%-65%, LTC according to tumor size (pT1-to pT4-ig) 100 %, 100%, 88% and 70%.

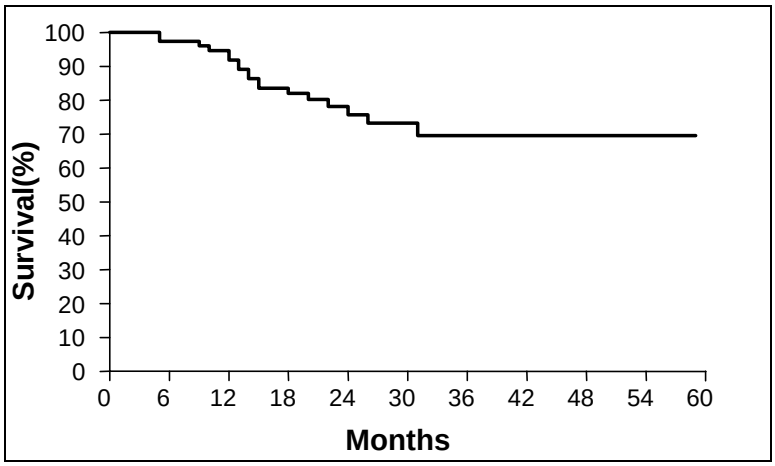

DIAGRAM 1. *The overall patient survival curve following surgery and postoperative radiation therapy (3years: 69%)*

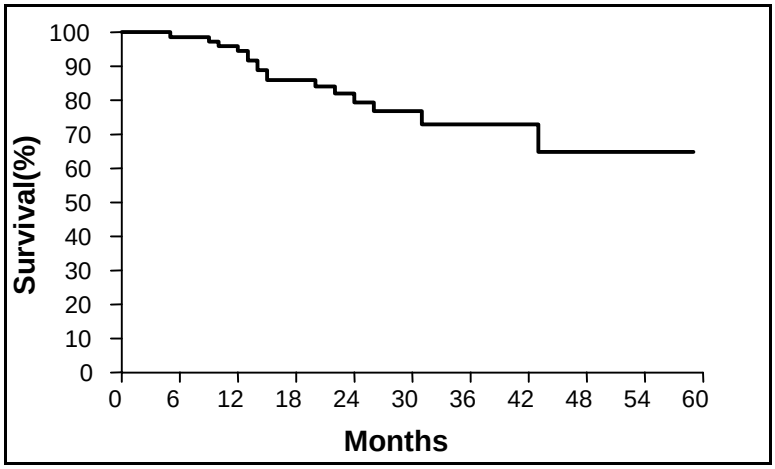

DIAGRAM 2. *Tumor specific survival curve of patients after primary surgical procedure and postoperative radiation therapy (3years: 71%)*

B./ Tumor excision due to recurrence, tissue replacement with free flap

The average follow up period of patients operated due to recurrent tumor as 21.5 months (9-58). In 5 percent of the cases distant metastases developed. We did not observe a second primary carcinoma during the follow up period, we did not lose any patients due to intercurrent disease. Recurrence, following surgery and postoperative treatment, occurred on average within 8.7 months (2-15) in 35% of the cases locally, and within 8 months (2-15) in 25% of the cases regionally. We were not able to carry out other surgical intervention due to recurrence. The LTC calculated with the Kaplan-Meier method for 3 years was 60%, the RTC (regional tumor control) 67%,

the OS and DSS ratio was 48% and 52%). The DSS according to stage I-IV. 100%-100%-73%-25%, LTC according to tumor size (T1-to T4-ig) 100 %, 68%, 67% and 54%.

C. /Prognostic factors influencing local and regional tumor free state and overall survival

In the group undergoing **primary surgery**, age, gender, advanced stage (I-III/IV), histologic grade, more than one positive lymph node did not influence the survival parameters. We did not find any factor that significantly influenced survival using a univarient analysis. The tumor specific survival (DSS) was negatively influenced by the advanced tumor size (T1-3 vs. T4 p=0.0331), the positive lymph node (pN0/pN+ p=0.0134), the regional localization of lymph node metastases, (single region N+/- multi region N+ p=0,0268) and perineural tumor advancement (p=0,0498). The local tumor free state (LTC) was negatively influence by the advanced tumor size (T1-3 vs. T4 p=0.0039), the positive lymph node (pN0/pN+ p=0.0499), perineural tumor advancement (p=0,0484), and bone infiltration by the tumor (p= 0,0165). The regional tumor free state (RTC) was negatively influenced by the positive lymph node (pN0/pN+ p=0,0186), the positive resection margin (R0/R+ p= 0,0051), and perineural tumor advancement (p=0,0425).

The age, gender, advanced tumor stage (I-III/IV), histologic grade, more than one positive lymph node did not influence the survival parameters in the patient group undergoing **salvage surgical** procedures. The negative predictors of overall survival (OS) and tumor specific survival (DSS) proved to be lymph node metastases (OS p=0,0124, DSS p=0,0045), extracapsular tumor advancement (OS p=0,016, DSS p=0,0058) and multi level lymph node metastases (DSS p=0,032). We did not find negative predictors for the local tumor free state. The size of the primary tumor, the negative surgical margin, the perineural advancement, bone infiltration or vascular invasion of the primary tumor could not be statistically established as indicators for the regional tumor free state. The statistically significant prognostic factors for the regional tumor free state proved to be the positive lymph node (p=0,0053), the N stage (p=0,0475) and the extracapsular tumor advancement (p=0,0009). The prognostic factors were the N stage (p=0,0081), the extracapsular tumor advancement

(p=0,0419) and multi region lymph node metastases (p=0,0267) for development of distant metastases.

Quality of life analysis

The postoperative quality of life questionnaire was received from 50 patients, 34 (68 %) males, 16 (32 %) females, 53.6 (26-75) years average age, mostly with basic or medium level education (78,8 %). The median score for the oral cavity functions questions dropped slightly one year postoperatively, however, the average for the eating in public (preoperative 91,3, postoperative 56,7), eating habits (preoperative 92,6, postoperative 58) and understanding of patient's speech (preoperative 95,8 postoperative 73,6) dropped by a level which was statistically significant.

A moderate correlation can be measured when analyzing the functional parameters between eating habits, meaning the chewability of the food and eating in public places. 18 %-(9/50) of the analyzed patients had discontinuity of the mandible upon removal of the tumor. The reconstruction took place in 89% (8/9) of the cases with reconstructive plates and free tissue transfer. The oncologic procedure was carried out with partial resection of the mandible with preservation of the continuity in 26% (13/50) cases, and in 56% of the cases (28/50), we only performed soft tissue resection. The pre- and postoperative scores were nearly the same without statistically significant differences. The main difference was found in patients that healed with a segment deficit.

The perioperative pain in the area of the primary tumor or radiating from it's location found in 95% of the cases scored 42.4 points on the visual analogue scale, while this score was 11.5 points postoperatively ($p<0.0001$). The patients' need for analgesics significantly decreased after the operation, all patients discontinued the use of narcotic analgesics. 11% of the patients had decreased range of motion of the shoulders before surgery, while this number dropped to 6% after surgery. 4% of the patients had problems with taste sensation preoperatively, and this number increased to 26% after treatment. 84% of the patients did not have dryness of the mouth prior to surgery, however, after surgery and postoperative radiation therapy the number of patients having this complaint increased to 86%, 14% of them had severe symptoms.

The 22 patients with tongue base tumor had better functional result, in all categories, on average by 28 points that the surgical group of patients. The largest difference was noticed in the eating habits. The irradiation treatment brought an improvement compared to the pre-irradiation scores in the eating habits and patient's speech understanding groups. The level of pain decreased from 42-40, however severe dryness of the mouth developed in 20%-, along with taste sensation disorders in 22% of the patients.

V. CONCLUSIONS

1. Oncosurgical procedures and related primary restorative surgeries, representing a major part of maxillofacial surgical interventions, can be built into everyday practice with two surgical teams having an adequate operating experience and intensive care background. By using well-practiced free flap techniques, deliberately adapted to reconstructive needs, the mean duration of surgery may be reduced to one shift: this can be a guarantee for the cost-efficiency emphasised today while maintaining the standards of patient care.

2. Micro-surgical restorative procedures, intentionally performed with well-known flap types and with adequate capacity, are reliable in terms of flap necrosis; the rate of overall surgical complications is acceptable. Surgery on relapses after radiotherapy cannot be undertaken without free tissue replacement in today's practice.

3. The majority of free flaps can be saved by early recognition of any micro-circulation disturbance to the flap and re-operation. This fact stresses the importance of precise, professional peri-operative monitoring. Circulation disturbance is usually caused by bleeding or compression. In cases of revascularisation failure, the use of a latissimus dorsi myocutaneous (LD) flap with reliable circulation as a second free flap is recommended instead of regional flaps.

4. Pre-operative radiotherapy does not increase the rate of complete flap necrosis complication, irrespective of the irradiation dose. However, due to tissue fibrosis induced by radiotherapy, surgical planning and careful consideration have greater importance.

5. The results obtained from primary surgery of tumours of the oral cavity showing advanced growth in the oral cavity and oropharynx and post-operative radiotherapy as well as with salvage surgeries (such as local tumour free status and tumour-specific survival), correspond with literature data. When studying the prognostic factors of 3-year tumour-specific survival in our patients who underwent primary surgery and radiotherapy, the size of primary tumour, lymph node metastasis and multi-regional tumour growth as well as perineural tumour invasion had negative effects; in patients who underwent salvage surgery only regional status (i.e. single and multiple and multi-regional lymph node metastasis and extracapsular tumour growth) had negative effects.

6. Surgical and adjuvant radiotherapy of advanced tumours of the oral cavity and oropharynx significantly impairs the function of the oral cavity, even when reconstructive surgery is done. This is mainly represented by the quality of eating and understandability of speech. By restoration of continuity to the jaw bone this functional impairment is not measurable compared to patients who underwent soft tissue replacement alone. The final rehabilitation can be achieved with a vascular pedicle bone graft transfer and prosthesis, on the group of patients where the dryness of the mouth caused by the radiation therapy is not severe. Because of the good therapeutic results and maintained quality of life, (chemo)radiotherapy is the treatment modality of choice in tongue base tumour localisation.

ARTICLES IN CONNECTION WITH THE SUBJECT OF THE THESIS

Takácsi-Nagy Z, **Oberna F,** Somogyi A, Polgár Cs, Major T, Németh Gy.: Experiences in the treatment of tumour of base of the tongue with high dose rate interstitial radiotherapy on the basis of a retrospective analysis Magyar Onkológia, 44: 117-121 (2000)

Oberna F, Remenár É, Pólus K.: Platysma myocutaneous island flap reconstruction after excision of a tongue-tongue base tumor Fogorvosi Szemle 2002;2:59-62

Oberna F, Réthy Á, Takácsi-Nagy Z, Pólus K, Kásler M.: Buccal flap reconstruction of oropharyngeal defects Magyar Onkológia, 45: 173-175 (2001)

Takácsi Nagy Z, **Oberna F**, Polgár C, Somogyi A, Major T, Németh G.: The importance of interstitial radiotherapy in the treatment of the base of tongue tumours: a retrospective analysis Neoplasma 48: 76-81. (2001) **IF:0,637**

Takácsi-Nagy Z, **Oberna F**, Polgár C, Somogyi A, Major T, Németh Gy.: Interstitial radiotherapy of cancer of the base of tongue Oral Oncology 7:256-260. 2001.

Oberna F, Iványi E, Udvaros I, Pólus K, Kásler M.:.Reconstruction of periorbital resection defects using the temporoparietal fasciocutaneous flap Magyar Traumatologia, Ortopédia, Kézsebészet és Plasztikai Sebészet XLIV/4: 290-295. (2001)

Takácsi-Nagy Z, **Oberna F**, Somogyi A, Major T, Németh Gy.: Modern radiotherapy techniques in the treatment of tumour of the base of tongue Magyar Onkológia, 45: 193-196 (2001)

Fülöp M, Remenár É, **Oberna F**, Boér A, Iványi E, Pólus K, Kásler M.: Radial forearm and fibula free flap reconstruction after radical resection of head and neck malignancies Magyar Onkológia 45/2: 177-180(2001)

Z.Takácsi-Nagy,Cs.Polgár, **F.Oberna**, A.Somogyi, T.Major, É.Remenár,J.Fodor, M.Kásler, Gy.Németh: Interstitial High-Dose-Rate Brachytherapy in the Treatment of Base of Tongue Carcinoma Strahlenther Onkol 2004, 180: 768-75 **IF:3,121**

F.Oberna, Z.Takácsi-Nagy, Á.Réthy, K.Pólus, M.Kásler: Buccal mucosal transposition flap for reconstruction of oropharyngeal-oral cavity defects: An Analysisof 6 cases. Oral Surg., Oral Surg Oral Med Oral Pathol Oral Radiol Endod. 2005 May;99(5):550-3 **IF: 1,193**

Kásler M, Takácsi Nagy Z, Oberna F, Fodor J.: Salvage surgery for lokoregional failure definitive radiotherapy for base of tongue cancer In Vivo. 22(6):803-806, 2008. **IF.:1,134**