New possibilities in the endovascular treatment of supraaortic vessels

Ph.D. Thesis

Balázs Nemes, MD

Semmelweis University
School of Ph.D. Studies, Basic Medicine

Supervisor: Kálmán Hüttl MD, Ph.D.

Reviewers: Péter Sótonyi, MD, Ph.D.
István Szikora, MD, Ph.D.

Chairman of the Exam Committee: Anita Kamondi, MD, Ph.D.
Members of the Exam Committee: Sándor Horváth, MD, Ph.D.
Zoltán Szabolcs, MD, Ph.D.

Budapest
2010

INTRODUCTION

Cerebrovascular disease, including stroke, represents the third-leading cause of death in Hungary and a leading cause of disability among the elderly population. The majority of all strokes are ischemic, mostly secondary to thromboembolic disease of the supraaortic vessels. We investigated new therapeutic methods in the endovascular treatment of these diseases. Surgical and interventional treatment of the supraaortic arteries is an established method of stroke prevention in both symptomatic and asymptomatic patients. Surgical revascularization of supraaortic trunk stenosis is associated with high morbidity and mortality rates. Less invasive balloon angioplasty and stenting has become an increasingly accepted treatment of stenoocclusive supraaortic arterial disease. Natural history data and treatment guidelines do not exist for innominate and proximal common carotid artery lesions. Carotid endarterectomy (CEA) has been the primary treatment for carotid stenosis since the 1950s, its effectiveness was proved by randomized trials in symptomatic (NASCET, ECST) and asymptomatic patients (ACAS, ACST). Stenting of the carotid artery was first performed in the 1980s, indications for CAS initially included cases when medical conditions precluding surgery (e.g., carotid restenosis, coronary artery or chronic pulmonary disease). Carotid stenting have become more widespread due to the introduction of embolic protection devices, but randomized controlled trials comparing CEA with CAS found significantly more minor strokes in stented patients. Several factors, including the stent design and the type of the embolic protection device, may influence the procedure complication rate;

OBJECTIVES

1. Surgical revascularization of innominate artery stenosis results in long lasting patency, these procedures are associated with elevated complication rates. We investigated the safety and long time effectivity of PTA in the treatment of innominate artery stenoses and occlusions.

2. Surgical revascularization of proximal common carotid artery (pCCA) is an effective and durable treatment; however, the stroke/death rate associated with the transthoracic approach was high which was reduced by the introduction of extra-anatomic repair. Our aim is to assess primary success and safety of endovascular treatment of ostial/proximal

common carotid artery lesions and to compare our results with the published data on the surgical options.

3. Stent design may affect technical success and complications in a certain subgroup of patients. We assess the wall adaptation of a new carotid stent (NexStent) in the carotid bifurcation by means of angiography and high-resolution computed tomographic angiography (CTA).

4. Early restenosis develops mainly within the first 24 months after the revascularization procedure and its pathological background is myointimal hyperplasia. Only a few studies have been done to compare carotid endarterectomy and stenting, with regard to the early restenosis rate after both procedures. We compare the early restenosis rate between patients undergoing carotid artery stenting (CAS) and carotid endarterectomy (CEA) at our institution**.**

5. Aneurysms of the internal carotid artery are dangerous lesions because of thromboembolism and, occasionally, rupture. Our aim is to treat carotid pseudoaneurysms using stent-grafts.

METHODS

1, Angioplasty of the innominate artery

Eighty-nine innominate artery lesions were treated with angioplasty. The diagnosis of innominate artery stenosis or occlusion was based on pulse palpation of the radial arteries, comparative blood pressure measurement on both arms, and carotid and vertebral duplex scan. Angioplasty was usually performed in the same session with angiography, via a femoral artery puncture in all but three cases, when axillary artery was utilized. Patients were discharged 1 day after the procedure; Aspirin (125 mg daily) was administered for at least 6 months after PTA. Follow-up examination was scheduled 6 weeks, 3 months and 6 months after PTA and yearly thereafter. For statistical analysis, the Kaplan–Meier method was employed to calculate cumulative primary and secondary patency rates.

2. Endovascular treatment of proximal common carotid artery lesions

One hundred fifty-three percutaneous transluminal angioplasties – including 108 stent deployments - were performed on 147 consecutive patients with significant proximal common carotid artery (pCCA) stenosis. Proximal CCA stenosis was diagnosed by catheter angiography following an initial duplex screening. Inclusion criteria for endovascular treatment were ≥70% luminal diameter stenosis in patients with ipsilateral ischemic neurologic symptoms or >85% stenosis in asymptomatic patients. Balloon expandable stents were used for ostial, self expandable stents for more distal lesions. Embolic protection devices were only used in cases when ICA stenting was performed during the same procedure. One hundred fifteen out of 147 patients had follow-up visits that included carotid duplex scanning and a neurological examination. The Kaplan-Meier method was employed to calculate patency rates, and the log rank test was used to compare cumulative patency rates between PTA and PTA/stent groups.

3. Evaluation of NexStent wall adaptation

Forty one patients underwent stenting (NexStent) of 42 carotid arteries after three days of pre-treatment with Aspirin and clopidogrel. Following diagnostic angiography, 8F guiding sheath was positioned in the common carotid artery and embolic filter was advanced and opened over the stenosis. The stent was deployed across the stenosis and subsequently dilated; patients with primary lesions received prophylactic i.v. atropine before balloon dilation. The femoral artery was closed by percutaneous closer device. Besides permanent administration of Aspirin, clopidogrel was continued for 6 weeks.

CTA examinations were performed by an eight-channel multidetector computed tomographic system using nonionic contrast material. CTA helped to quantify plaque calcification and evaluate of wall apposition and proper overlapping of the stent layers. The relationship between the amount of plaque calcification and the residual stenosis after stenting was tested by Spearman's rank correlation. The adaptation between stent and vascular anatomy were evaluated on angiograms with the following criteria: (1) stent coverage of the plaque; (2) stent-induced kinking of the ICA; and (3) apposition (free area between stent and vessel wall).

4. Early restenosis after eversion carotid endarterectomy versus carotid stenting

Data were retrospectively collected from our database, listing all patients who underwent CEA or CAS during 2004 at the Department of Cardiovascular Surgery, Semmelweis University. During the mentioned period, 206 CAS procedures were performed on 201 patients and 479 CEA were undertaken on 453 patients; 144 CAS and 368 CEA patients were available for follow up. Six (1,63%) of the surgical and 44 (30,55%) of the stented patients were treated for restenosis. The mean follow-up time for CEA and CAS patients were 17.9 months (range 6–38 months) and 19.8 months (range 6–36 months), respectively (P=NS). The evaluation of carotid restenosis was performed by US; the diagnostic criteria for ICA restenosis were based on PSV, EDV as well as ICA/CCA PSV ratios. Freedom from restenosis rates was estimated with the Kaplan-Meier method, using log-rank test for comparison of groups

5. Stent graft treatment of carotid pseudoaneurysms

Two patients with extracranial carotid aneurysm were treated by stentgraft implantation. One of them underwent ultrasound guided aspiration cytology; six months later a pulsatile mass at the right mandibular angle was noticed. The other patient had carotid endarterectomy in the anamnesis. The diagnosis was established using duplex scan and confirmed by CT angiography. Through a 10F introducer, 50 mm long 10 mm diameter Wallgraft was deployed across the neck of the aneurysm. After deployment the stent was dilated using an appropriate size PTA balloon to assure fixation to the wall. Control angiography showed no contrast extravasation into the aneurysm.

RESULTS

1. Angioplasty of the innominate artery

The technical success rate was 96.6% (86/89); one patient (1,1%) suffered stroke. There were 2 puncture site thrombosis that needed surgery (2,2%). Clinical follow-up was available for 63% of the patients; 3 patients with restenosis were found, two of them were symptomatic and underwent re-PTA. Cumulative primary patency was 93±4%, secondary patency was 98±2% at the end of the follow up period (117 months) (Figure 1.).

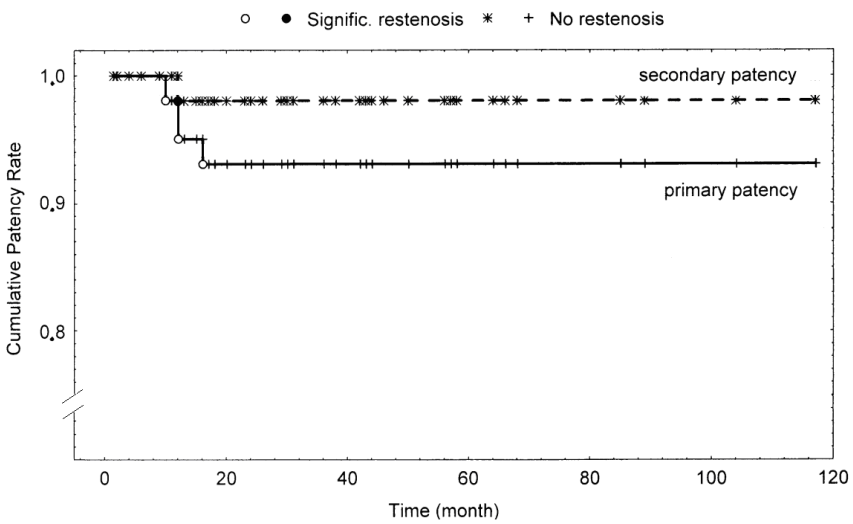

Figure 1. Patency rate for innominate artery interventions, excluding initial failures

2. Endovascular treatment of proximal common carotid artery lesions

Technical success rate was 98.7% (151/153), 3 strokes (2%) and 4 puncture site bleedings (2,6%) occurred. The mean follow up time was 24,7 months, 78.4% of the patients were available for follow-up evaluation. During the follow up period 3 reocclusions and 7 restenosis was found; we performed 6 reinterventions, one of the patients refused the procedure. From the aforementioned 6 cases we found three nonsignificant restenosis afterwards. Cumulative patency rate was calculated using Kaplan-Meier method (Figure 2.). Log-rank test showed no statistical difference in primary (Figure 2, B) and in secondary cumulative freedom from restenosis between PTA alone or PTA/stent.

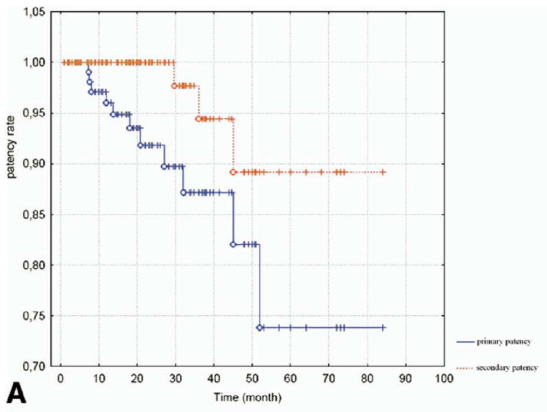

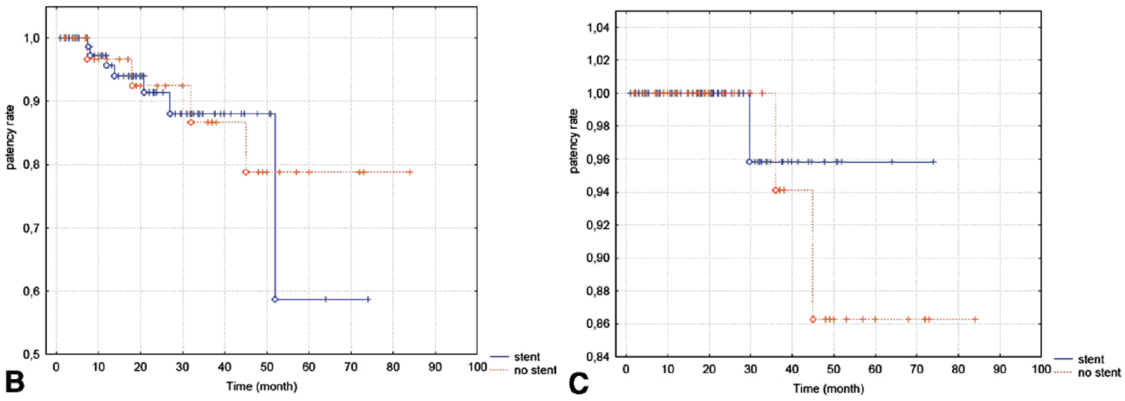

Figure 2. A) patency rate for proximal common carotid artery interventions B) primary patency rate for proximal common carotid artery angioplasty and stent implantation, log rank test: P=0.825. C) secondary patency rate for angioplasty and stent implantation, log rank test: P=0.680

3. Evaluation of NexStent wall adaptation

Twenty-five bifurcations had straight anatomy; in 12 cases slight and in 5 cases significant tortuosity was noticed; in the last group control angiography showed one poststent angulation and one kink formation. The residual stenosis and the amount of calcification showed weak correlation (Spearman correlation coefficient=0.345, P=0.0154). Incomplete stent apposition was identified and measured on angiographic images in 12 cases; six of them were associated with the seven ulcerative lesions seen on the diagnostic angiogram. The unrolling of the stent was complete in all cases; there was no layer protrusion or infolding into the lumen.

4. Early restenosis after eversion carotid endarterectomy versus carotid stenting

No difference between groups in terms of stroke and myocardial infarction was observed, significantly more transient neurological symptoms occurred after CAS than after surgery. Restenoses were categorized as mild (<50%), moderate (50–69%) and severe (≥ 70%). Evaluation with the Kaplan-Meier life table analysis showed a significant difference in freedom from both moderate and severe restenosis between the CEA and CAS groups in favor of the stent (Figure 3 and 4).

Restenosis	CEA	CAS		Primer CAS	
Moderate (50-69%)	11.41% (42/368)	4.86% (7/144)	P=0.025	4% (4/100)	P=0.016
Severe (≥70%)	10.05% (37/368)	3.47% (5/144)	P=0.006	2% (2/100)	P=0.002

Figure 3. Restenosis in the CEA and CAS group at the end of the follow up period (18.4 months)

The statistical significance was even more pronounced when CEA was compared with primary stenting (Figure 5). Logistic regression analysis was performed to assess variables associated with moderate and severe restenosis. Univariate analysis showed that female gender was associated with severe restenosis irrespectively of the interventional technique (OR: 2.02 [CI: 1.07–3.80], P=0.028). The odds ratio was found to be higher when only those patients were selected who underwent CEA (OR: 2.61 [CI: 1.28–5.32], P=0.006).

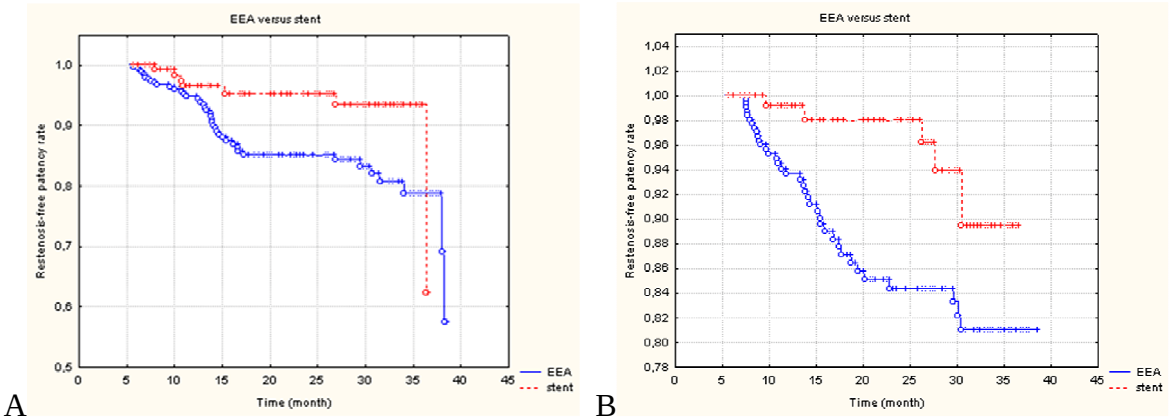

Figure 4. Freedom from restenosis, comparison of all CEA and all CAS cases. A) Kaplan-Meier analysis of moderate (50-69%) restenosis for CEA and CAS groups (P=0.025); B) Kaplan-Meier analysis of severe (≥70%) restenosis for CEA and CAS groups (P=0.006).

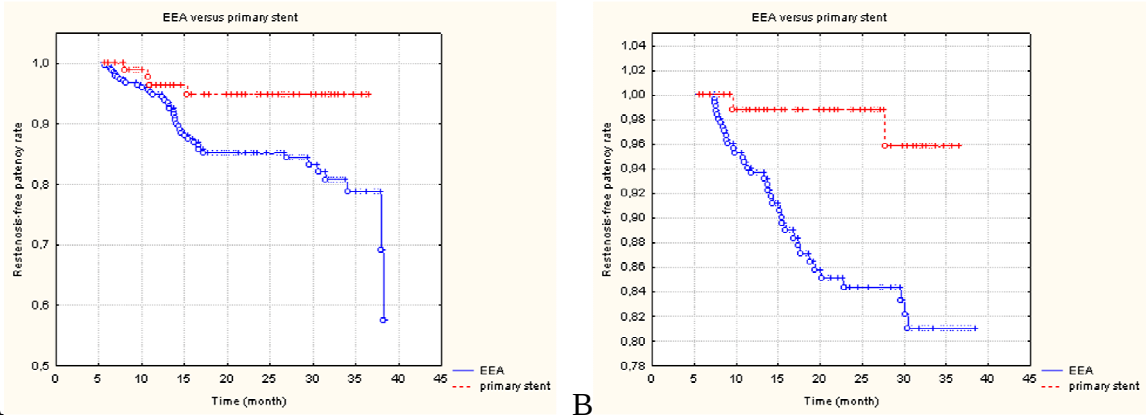

Figure 5. Freedom from restenosis, comparison of all CEA and primary CAS cases. A) Kaplan-Meier analysis of moderate (50-69%) restenosis for CFA and CAS groups (P=0.016); B) Kaplan-Meier analysis of severe (≥70%) restenosis for CEA and CAS groups (P=0.002)

5. Stent graft treatment of carotid pseudoaneurysms

One of the patients remained asymptomatic at the 6 weeks, 6 months and 1 year follow-up examinations. Duplex US demonstrated patent carotid artery with continued obliteration of the pseudoaneurysm during the follow-up period.

The second patient underwent repeated duplex examination on the postoperative 3rd day because of amaurosis of the left eye and revealed occlusion of the endograft. Follow-up neuro exams showed no neurological symptoms.

CONCLUSIONS

1. We have confirmed in a large series of innominate artery angioplasties that it is a safe and effective procedure with an excellent initial success rate, without any lethal complication, with a lower complication rate than the surgical option and with a similar long-term patency rate as surgery.

2. We published the largest study on angioplasty of ostial and proximal common carotid artery stenosis. The primary technical success rate is high with a low stroke/death rate.

3. Good plaque coverage and proper overlapping of the rolled sheet was achieved in all cases. The longitudinal flexibility of the stent is limited, as for all other closed-cell stents; in tortuous vessels, kink formation may occur. The stent provided adequate expansion and

wall adaptation. We found weak correlation between the residual stenosis and the amount of plaque calcification; incomplete stent apposition was associated with plaque ulceration.
4. Our results showed that both moderate and severe restenosis occurred statistically less frequently in the CAS than in the CEA group. Female gender was associated with severe restenosis irrespectively of the interventional technique. We compared CEA patients to a subgroup of CAS patients with primary carotid stenosis, which resulted in a more significant difference between restenosis rates of CEA and CAS.
5. Aneurysm of the internal carotid artery can be successfully treated using stentgrafts. The relatively low incidence of these lesions makes difficult to compare the different treatment methods.

PUBLICATIONS

Papers with relevance to the current work

Hüttl K, **Nemes B**, Simonffy A, Entz L, Bérczi V. Angioplasty of the innominate artery in 89 patients: experience over 19 years. Cardiovasc Intervent Radiol 2002; 25:109-114.

Nemes B, Járányi Z, Bérczi V, Hüttl K, Acsády G. Stent-graft Treatment of Carotid Pseudoaneurysms: Case Report and Review of the Literature. European Journal of Vascular and Endovascular Surgery 2005; 30:449.

Paukovits TM, Haász J, Molnár A, Szeberin Z, **Nemes B**, Varga D, Hüttl K, Bérczi V, Léránt G. Transfemoral endovascular treatment of proximal common carotid artery lesions: a single-center experience on 153 lesions. J Vasc Surg 2008; 48:80-87.

Hirschberg K, Dósa E, Hüttl K, Selmeci L, **Nemes B**, Szabó A, Merkely B, Acsády Gy, Entz L. Early restenosis after eversion carotid endarterectomy versus carotid stenting: a single-centre retrospective study. J Cardiovasc Surg (Torino) 2009; 50:655-663.

Nemes B, Lukács L, Balázs G, Dósa E, Bérczi V, Hüttl K. High-resolution CT and angiographic evaluation of NexStent wall adaptation. Cardiovasc Intervent Radiol 2009; 32:436-440.

Abstracts

Bérczi V, Szlávy L, Simonffy Á, **Nemes B**, Hüttl K. Angioplasty of the supraaortic arteries - a 18 year experience on 632 cases. Cardiovasc. Intervent. Rad. 1997; 20 Suppl 1:S83.

Nemes B, Dzsinich C, Bérczi V, et al. PTA and surgical revascularization of the innominate artery. Cardiovasc. Intervent. Radiol. 1998; 21 suppl. 1:231.

Bérczi V, Entz L, Gellér L, **Nemes B**, Simonffy A, Hüttl K. [Percutaneous angioplasty of the innominate artery in 89 patients: experience of 19 years]. Magy Seb 2001; 54 Suppl:19-23.

Bérczi V, Molnár AÁ, **Nemes B**, Varga D, Simonffy Á, Hüttl K. Az arteria carotis communis eredésének intervenciós radiológiai kezelése. Érbetegségek 2004; suppl.:E18.

Nemes B, Dósa E, Simonffy Á, Hüttl K. Az arteria carotis interna stentelése filteres embóliavédő használatával. Érbetegségek 2005; suppl.:16.

Entz L, Hüttl K, **Nemes B**. Az arteria anonyma angioplasztikája 129 betegen: 26 év tapasztalata. Érbetegségek 2006 suppl.:32.

Hüttl K, Hirschberg K, Dósa E, **Nemes B**, Entz L. Retrospectiv tanulmány carotis interna sebészi és stentelése után kialakult restenosis arányának felmérésére és összehasonlítására. Cardiologica Hungarica 2008; 38 B35.

Nemes B. Proximalis embóliavédelemben végzett carotis stenteléssel szerzett tapasztalataink. Érbetegségek 2008; suppl.:73 E74.

Entz L, Szabó A, Járányi Zs, **Nemes B**, Hirschberg K, Dósa E, Hüttl K. Az a. carotis interna stenosisa: stentelés vagy endarterectomia – az érsebész nézőpontjából. Vascularis Neurológia 2009; suppl 1:28.

Hüttl K, Lukács L, **Nemes B**. Stent törés előfordulása anonyma intervenciós kezelését követően. Cardiologica Hungarica 2009; 39.

Nemes B. Carotis interna stentelés proximalis embóliavédelemben. Cardiologica Hungarica 2009; 39 A72.

Nemes B, Hirschberg K, Dósa E, Hüttl K. Az a. carotis interna stentelésével szerzett tapasztalataink, 1465 eset kapcsán. Vascularis Neurológia 2009; suppl 1:28.

Other publications

Nemes B, Szlávy L, Hüttl K, Repa I, Simonffy Á. Unusual cases of subclavian steal syndrome, their treatment by PTA. Subclavian steal syndroma atipusos formái és kezelésük percutan transluminalis angioplasztikával (PTA). Ideggyógyászati Szemle (Clin. Neurosci.) 1992; 45(9–10):306-312.

Hüttl K, Sebestyén M, Entz L, Molnár AA, **Nemes B**, Bérczi V. Covered stent placement in a traumatically injured vertebral artery. J Vasc Interv Radiol 2004; 15:201-202.

Hüttl K, **Nemes B**, Dósa E, Varga D, Bérczi V. A carotis szűkületek stenteléssel történő kezelése. Magyar Sebészet 2007 60(1):488-493.