INTERVENTIONAL RADIOLOGICAL TREATMENT OF COMPLICATIONS AFTER LIVER TRANSPLANTATION

Doctoral theses

Attila Doros MD

Semmelweis University
Pathological Medicine Doctoral School

Supervisor: László Kóbori, MD, PhD

Opponents: András Palkó, PhD, Dsc

László Harsányi, MD, PhD

Head of the exam committee: Viktor Bérczi, PhD, Dsc

Members of the exam committee: Gábor István, MD,PhD

István Lázár, MD, PhD

Budapest
2009

1. Introduction

Liver transplantation is the only, widely accepted successful treatment of end stage liver disease. During the 40 years history of liver transplantation the results have been continuously improved due to the refinements in surgical techniques and development of immunosuppressive drugs. Scarcity of the available livers from deceased donors results in prolonged waiting time in the liver transplantation waiting lists. Preserving the function of the transplanted organ is of utmost importance. One of the usual therapy of several serious complications is retransplantation, but, besides the lack of availability of donor organs, one should take into account the increased postoperative mortality and morbidity of liver retransplantation.

Despite of the unequivocal evolution of the surgical procedure of liver transplantation complications can not be eliminated totally. These complications present a serious risk to the life of the patient and survival of the graft liver.

Traditional treatment of complications is surgery, and at last retransplantation. Besides surgical methods minimally invasive treatment modalities are gaining wider acceptance. The technical refinements of catheters, guidewires and stents made this possible. One major advantage of minimally invasive treatments is being more tolerable for the patients compared with surgery. Another important issue is that these interventions might be repeated several times, and in case of a suboptimal result, surgery usually remains as a still performable option.

Conservative medical therapy is applicable for immunological reactions, such as acute and chronic rejection, viral bacterial and mycotic infections. Minimally invasive, interventional radiological treatments are used

to treat complications related to the surgical techniques, or consequences of infections or prolonged ischemia.

As in other fields of medicine, two major group of interventional radiological treatments developed: vascular and non-vascular. The same is true according to the field of liver transplantation. In vascular complications only endovascular, catheter-driven methods may be applied from the minimally invasive treatment group, while in the non-vascular group interventional endoscopy has an important role. Biliary complications may be treated by means of endoscopy, interventional radiology, or surgery, even combination of these therapies could be possible.

Interventional radiological methods have been available from the birth of the Hungarian Liver Transplantation Program. During the last 14 years interventional radiology went through its largest and most influential development by means of the quality of devices, such as catheters, stents, drains, and imaging equipments. Nowadays, treatment of vascular and non-vascular complications is based on interventional radiology, little place is being left for endoscopy. Surgery is involved only when minimally invasive treatments proved to be unsuccessful.

These days a basically new concept is being shaped concerning interventional radiological treatments of complications after liver transplantation. The question is, are these methods of value preserving liver function, can they prolong the lifetime of the donated organ? Is it possible to prevent the development of serious damage of parenchyma and bile ducts, could we avoid retransplantation? According to this issue, the most important types of postoperative complications are the early arterial and venous disturbances and intrahepatic biliary strictures, otherwise possible to treat exclusively with retransplantation. In this study I focused on the results of the

interventional radiological therapy of the abovementioned complications, concentrating on the necessity of liver retransplantation.

2. The aim of the study

1. Is it possible to restore or maintain the hepatic arterial flow in early strictures or thrombosis after liver transplantation? Surgical or interventional methods can be applied better concerning tolerability of the treatments, survival of the donor liver and the patient?
2. Is it safe and feasible to treat early postoperative portal vein stricture with percutaneous transhepatic portal vein catheterization and metallic stent placement. Is it possible to avoid reoperation or retransplantation?
3. Is it safe and feasible to treat early postoperative inferior caval vein stricture with percutaneous catheterization, balloon dilatation and metallic stent placement. Is it possible to avoid retransplantation?
4. Are self expanding metallic stents of value in treatment of intrahepatic, non-anastomotic biliary strictures? Can symptoms caused by biliary obstruction successfully relieved with this therapy? Is it possible to avoid an otherwise indicated retransplantation?
5. According to my results is it possible to elaborate useful diagnostic and therapeutic algorithms concerning the main complication-types?

3. Methods

3.1. Therapeutic possibilities of early postoperative arterial complications after liver transplantation

The analysis of the treatment of early postoperative arterial complications was based on the 365 liver transplantation performed in our department between 1995 and 2008. Early postoperative period was determined being between the first and 30th days. I found 25 patients (7%) having the diagnosis of early arterial complication. Adult whole liver transplantations were performed in 24 cases from deceased donors, while in one case adult-to-adult right lobe living donation was applied. Pure hepatic arterial thrombosis (HAT) was diagnosed in 12 cases, in 8 occasions hepatic arterial stricture (HAS) was found, while hepatic arterial thrombosis and stricture (HAT+HAS) existed together in 5 patients.

Two groups of patients were divided according to the primary treatment modality.

The Interventional Group consisted of 10 patients, treated primarily endovascularly with balloon dilatation (PTA), metallic stent placement and/or thrombolysis.

The Surgical Group consisted of 15 patients with primary surgical therapies, such as reoperation, revision of arterial anastomosis or retransplantation.

The main imaging modalities to diagnose arterial complications were color Doppler ultrasound (CDUS), computed tomography (CT) and angiography (DSA). All the patients had CDUS examinations routinely.

In the Interventional Group endovascular therapy was started after CDUS only in 6 cases, using DSA as an invasive imaging tool as well. CT-angiography was performed in 4 cases preceding interventional radiological treatments.

In the Surgical Group 3 patients were treated immediately after the diagnosis made by CDUS alone. CT-angiography was performed after suggestion of arterial complication by CDUS in 8 patients, and DSA was utilized to secure the correct diagnosis in 5 occasions.

All the PTA-s were performed on a 0,018 "(inch) or 0,014" system. The latter as developed primarily for percutaneous transluminal coronary angioplasty (PTCA). Two balloon expandable metallic stents were implanted. One of them was 4mm diameter 12 mm long Palmaz stent over an 0,018" guidewire, and the second one was a 3,5mm diameter, 12mm long coronary stent over a 0,014" guidewire. In the third patient an 8mm diameter, 60mm long self-expanding nitinol metallic stent was implanted into the obstructed arteria iliaca interpositum graft. In cases, when thrombolysis was required recombinant tissue plasminogen activator was used intra-arterially in an amount of 15-30 mg utilizing small dosages repeatedly. Fourteen interventions were performed in the 10 patients of the Interventional Group. Balloon dilatation was applied in 6 cases, 3 stents were implanted and in 5 occasions thrombolysis were performed.

In the Surgical Group all the therapeutic interventions were performed by our transplant surgeons. Surgical revision of the anastomosis,

which included the necessary mechanical thrombectomy was applied in 9 cases. Iliac artery interpositum graft harvested form the donor was used as an aorto-hepatic graft in 4 patients. Two patients went through retransplantation as a primary treatment option. In the 15 patients, consisting the Surgical Group 15 surgical treatments were performed.

3.2. Therapeutic possibilities of early postoperative portal vein strictures after liver transplantation

The analysis of the treatment of early postoperative portal vein anastomotic strictures was based on the 365 liver transplantation performed in our department between 1995 and 2008. Early postoperative period was determined being between the first and 30th days. I found 3 patients (0,07%, Nr. 1.: 49 years old female patient, Nr. 2.: 29 years old female patient, Nr.3.: 47 years old male patient) having the diagnosis of early portal vein stenosis. All the three liver transplantation were performed using livers from deceased donors. The mean age of the donors was 31 years.

The stenosis was caused by torsion of the anastomosis in all cases. Therapeutic intervention was started with an ultrasound guided fine needle (21-22G) percutaneous transhepatic punction of thw portal vein, followed by insertion of a coaxial dilator system 6F in size, using Seldinger technique. To negotiate the stenosed part of the portal vein hydrophilic guidewires and side-branch catheters were used. Percutaneous balloon dilatation of the stenosed portal vein was considered too risky, being in the early postoperative period, so self-expanding metallic stents were implanted primarily. In 2 patients nitinol stents (10 mm in diameter, 40mm in length), and in one case stainless steel-vanadium stent (11 mm in diameter, 38mm in length was applied. All the three stents expanded immediately.

3.3. Therapeutic possibilities of early postoperative inferior caval vein strictures after liver transplantation

The analysis of the treatment of early postoperative inferior caval vein (IVC) strictures was based on the 365 liver transplantation performed in our department between 1995 and 2008. Early postoperative period was determined being between the first and 30th days. Eleven patients with 12 IVC strictures were identified during this period (3%). One of these 12 patients had to undergo retransplantation (ReTx) for symptomatic retrohepatic IVC narrowing, but symptoms developed again with the new liver graft.

The usual sigs and symptoms caused by IVC strictures are: increasing, or not decreasing amount of free abdominal fluid, hydrothorax, body and leg edema, liver and kidney function disturbances. Objective measurements, such as an increased pressure gradient between the IVC and superior caval vein (SVC) should reinforce the suspicion of an IVC stricture.

For treatment 8 balloon dilatations were performed in 6 patients, while 6 patients received metallic stents. Knowing the fact that early IVC strictures are caused mainly by torsion of the vein at the anastomosis sites, and fibrotic strictures can be definitely excluded, large balloon catheters (10-25mm in diameter, 40mm length) and large stents (12-24mm in diameter, 38-70mm length) had to be applied.

In one occasion a large balloon expandable metallic stent (Palmaz) was used, in the remaining cases 5 self expandig metallic stents (Wallstent) were implated. During all interventions control SVC-IVC pressure gradient measurements were performed.

3.4. Therapeutic possibilities of non-anastomotic itrahepatic strictures after liver transplantation

The analysis of the treatment of non-anastomotic intrahepatic biliary strictures was based on the 365 liver transplantation performed in our department between 1995 and 2008. Early postoperative period was determined being between the first and 30th days. Twenty patients with such strictures were identified during this period (5%). In all the 20 cases minimally invasive treatment of the strictures were attempted.

Percutaneous biliary drainage and balloon dilatation of the strictures were the first line therapeutic option. For dilatation 5-8mm diameter, 20-40mm long high pressure (6-20 Atm rated burst pressure) balloon catheters were used. Altogether 58 dilatations were performed in 16 patients (a mean 3,6 dilatations per patient, maximum number of dilatation sessions: 6/patient). Following the dilatations an external or internal-external drain remained in the bile ducts for further control, and access. Control cholangiography were usually performed after 7-14 days, and, according to the findings, repeated dilatations or stent placements were decided. In 2 cases metallic stent insertion were performed after the first control cholangiography. In 14 cases further dilatations were decided and performed, but in 11 patients after the repeated control cholangiographies, due to the elastic recoiling of the strictures, metallic stent insertion became necessary. Altogether 20 self expanding metallic stents (14 nitinol, 6 Wallstent) implantations were performed. One of the patients received 3 stents, 5 patients had 2 stents and 7 patients undergone implantation of one stent. External biliary drainage was applied after stent implantations for 2-10 days. The external drains were removed after control cholangiographies with satisfactory results and in cases of stable clinical state. In 2 patients an external drain had to be left in non-communicating bile ducts

to treat the symptoms consisting of fever and icterus. In 8 patients concomitant arterial complications, in one patient a portal vein complication was present.

3.5. Satistical analysis

SPSS for Windows Software Pack was applied for the statistical analysis of the examined group of patients. Descriptive statistical analysis, Fisher's Exact test, t-test linear regression analysis, ANOVA test and chi-square test helped in the analysis of the data. The $p<0,05$ was determined as the level of significance. A meticulous search of the literature was performed to compare the results of several treatment methods and the therapeutic choices of different centres. In the examined complication types (except the very rare portal vein strictures) the following databases were interrogated: PubMed, Scopus, Ovid Medline and the Cochrane databases. In the portal vein strictures, having just 3 patients, only descriptive statistical analysis was performed.

4. Results

4.1. Result of treatment in early hepatic artery complications

Of the 25 patients with hepatic artery thrombosis or stenosis treated by means of surgery or interventional radiology 12 (5 of the 10 patients in the Interventional Group, 7 of the 15 in the Surgical Group) remained symptomless during the follow-up time. In 7 cases biliary strictures of ischaemic origin developed, 4 of them could be successfully treated percutaneously (3 of 10 in the Interventional Group, 1 of 15 in the Surgical

Group). Comparing the results of the two groups, 10% (1 of 10 patients) was lost in the Interventional Group, in contrast to the Surgical Group, where 33% (5 of the 15 patients) died after surgical treatments.

Retransplantation became necessary in 10% (1 of the 10 patients) in the Interventional Group, an in 20% (3 of the 15 patients in the Surgical Group). Biliary complication was more frequent in the Interventional Group (40%, 4 of 10 patients) than in the Surgical Group (20%, 3 of 15 patients). These complications were successfully treated in 3 and 2 patients accordingly. During the follow-up period 8 of the 10 (80%) hepatic arteries in the Interventional Group, and 9 of the 15 (60%) hepatic arteries in the Surgical Group are patent. I compared the therapeutic results in the Interventional and Surgical Groups using the chi-square test and didn't find any significant differences (p=0,865).

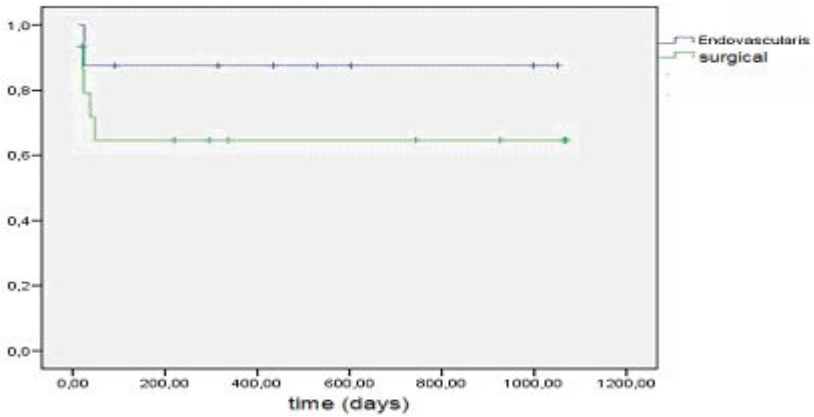

1. image: Survival results of surgical and interventional treatments. The survival benefit for the interventional (endovascular) therapies are the consequence of the mortality in the first 28 days (mean time, 12-48 days).

I censored the follow-up time at a maximum of 3 years and compared the survival curves in the two groups of patients, and found an obvious survival benefit for the interventional therapies. The main reason of this can be derived form the fact, that we lost all the 5 patients in the Surgical Group during the first 28 days (mean, 12-48 days) (1.image). I prepared a diagnostic and therapeutic algorithm after analyzing the results of this study (2.image).

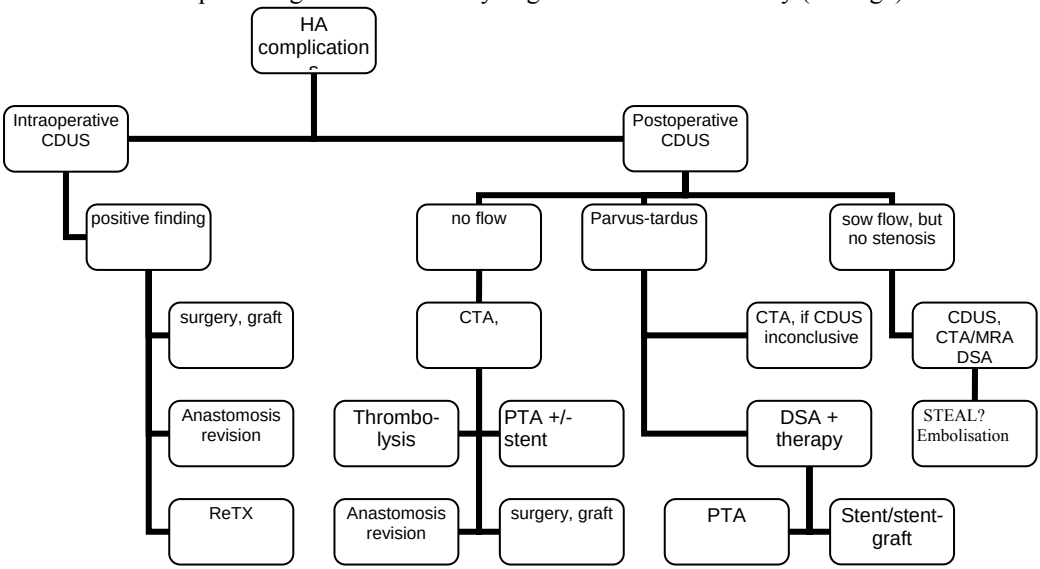

2.image: Diagnostic and therapeutic algorithm in cases of suspected arterial complication after liver transplantation.

4.2. Result of treatment in early postoperative portal vein complications

During the early postoperative period 3 patients were identified with significant anastomotic stenosis of the portal vein. These complications were treated with interventional radiological methods. All the 3 interventions were successful, and were performed 29, 28 and 22 days after liver transplantation.

The stents expanded immediately after implantation and free flow of the contrast material could be observed. We measured the pressure gradient in one occasions and found a 12 Hgmm (from 15 to 3 Hgmm) decrease after the stent implantation. We couldn't diagnose any complications during the treatments. After a 10 months and 39 months of follow-up 2 patients are well and symptomless. The 3rd patients had multiorgan failure 1 month after stent placement, and died despite of the multidisciplinary therapeutic efforts.

I prepared a diagnostic and therapeutic algorithm for patients of suspected portal vein stenosis after liver transplantation (3.image):

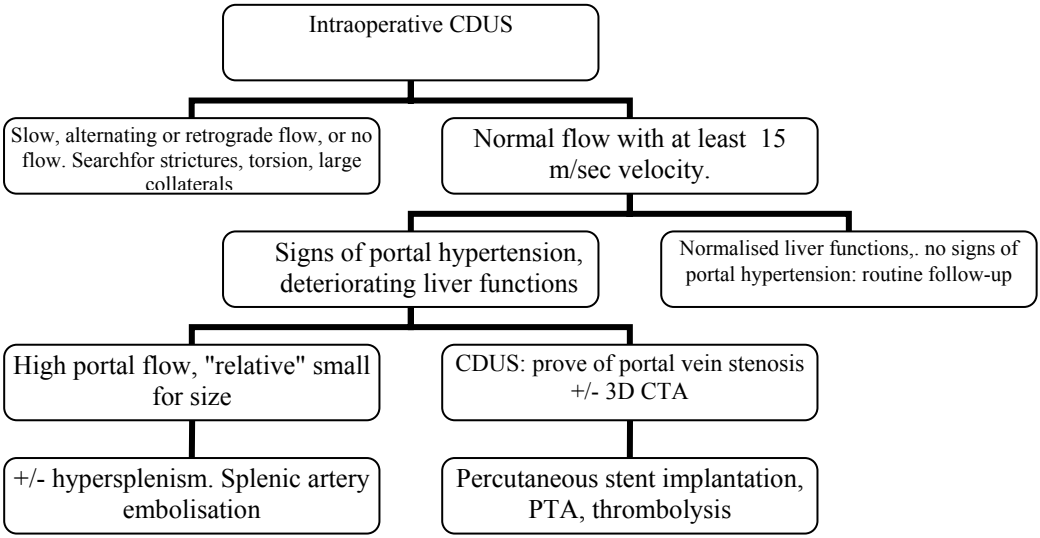

3. image: Diagnostic and therapeutic algorithm in cases of suspected portal vein strictures.

4.3. Result of treatment in early postoperative inferior caval vein complications

The treatment of strictures of the inferior caval veins (IVC) was started 25 days (mean time, 2-64 days) after liver transplantation. Either percutaneous balloon dilatations and stent implantations could be successfully performed in all cases. Kidney function was stable only in one patient. Six of the remaining 11 patients had reversible renal failure. We encountered 5 irreversible renal failure in 4 patients. One of this 4 patients had retransplantation developing the same symptoms of retrohepatic IVC stricture. This patient redeveloped renal failure and died later due to multiorgan failure. Among the patients with deteriorating kidney functions 2 died due to septic complications.

Concerning the treatment results I divided the patients into 2 groups: symptom-free (pleural fluids, ascites not requiring targeted treatment, reversible renal failure) and with symptoms. I compared the results of the 2 groups with t-test according to the time-gap between the diagnosis and treatment: Syptom-free / With symptoms: 22,0±24,7 days / 28,6±22,8 days, p=0,645. The result is not significant.

Closer, but still not coherence can be demonstrated with t-test between the renal function impairments and the time-gap from diagnosis to proper treatment, even with the small number of patients: reversible or not affected kidney function/ irreversible or chronic renal failure: 17,7±21,7 days / 37,2±21,1 days. p=0,151.

We performed invasive pressure gradient measurements prior and after treatment between the SVC an IVC and found an average decrease of 6 Hgmm (14 Hgmm, 9-18 Hgmm to 8 Hgmm, 3-14 Hgmm). A significant decrease of the pressure gradient was found in favor of the stent placements comparing to the PTA (p=0,019) (1.table).

1.table: Comparison of PTA and stent implantation results according to the decrease of pressure gradients

Therapy	Mean	Nr. of patients	St.deviation
PTA	4,3333	6	1,21106
Stent	6,8333	6	1,83485
All	5,5833	12	1,97523

p: 0,019

I prepared a diagnostic and therapeutic algorithm for patients of suspected IVC stenosis after liver transplantation (4.image):

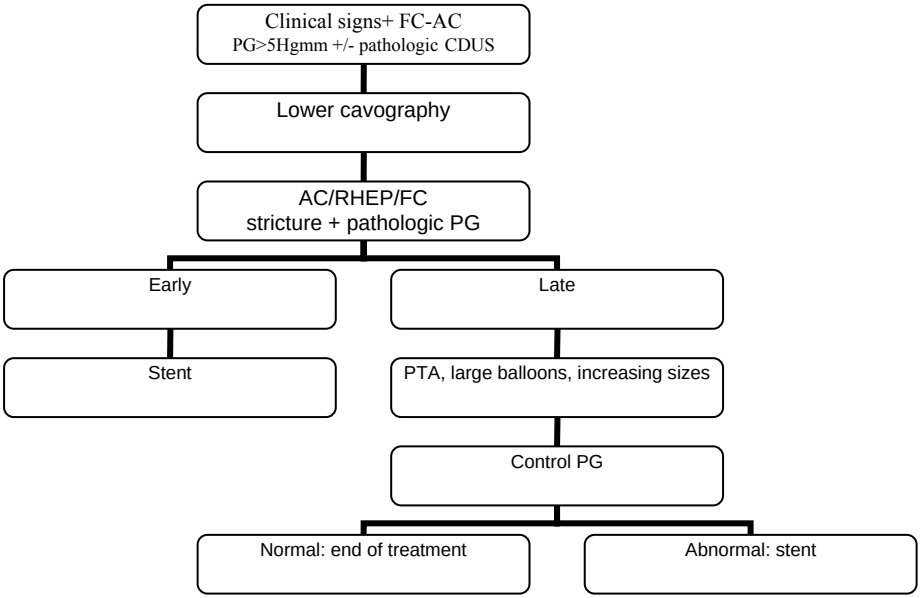

4.image: Diagnostic and therapeutic algorithm for patients with suspected IVC complications

4.4. Results of treatments in non-anastomotic intrahepatic biliary strictures after liver transplantation

We had 13 patrients with implanted metallic stents. Eleven of the 13 patients have patent metallic stents, but in 5 cases reintervention with percutaneous drainage and balloon dilatation had to be performed due to in-stent restenosis. In one patient an external drain had to be left in the occluded peripheral bile ducts despite of a patent stent to maintain an acceptable serum Bilirubin level.

I followed 14 symptom-free patients (no, or minimal signs of biliary obstruction) of whom 12 patients went through stent implantation. Two of these patients had to undergo retransplantation. Two more patients were retransplanted, one after balloon dilatation and one after external drainage. All the patients are alive after metallic stent implantation. The main follow-up time after the last intervention was 35 months. The longest follow up time was 151 months (approximately 13 years).

I compared the different stent-types concerning the decrease of the serum Bilirubin levels, the necessities for reintervention and didn't find any statistically significant difference. In average 70 μmol/L constant decrease of serum Bilirubin level could be achieved, and reinterventions were performed in every second patients. The average number of reinterventions were 1,33 per patient.

I prepared a diagnostic and therapeutic algorithm for patients of suspected biliary complications after liver transplantation (5.image):

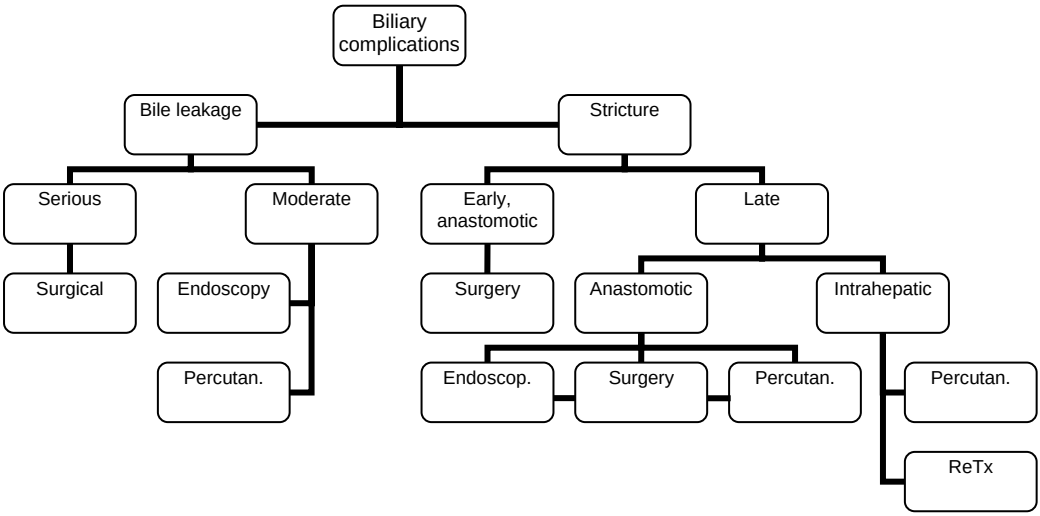

5.image: Diagnostic and therapeutic algorithm for patients with suspected biliary complications

5. Conclusions

1. Based on my experience and analysis of the collected data I could show that in cases of early hepatic artery complications the effectiveness of interventional radiological treatment modalities not differs significantly from the effectiveness of the surgical methods. However, it is obvious that the interventional radiological treatment modalities are more tolerable. The interventional radiological therapeutic options represent a real alternative to the surgical methods. The successful balloon dilatation, thrombolysis and stent implantation can restore the arterial inflow of the liver even in the early postoperative period. With these techniques the late complications of arterial inflow can be avoided, the function of the transplanted liver can be maintained, leaving possible the surgical methods in cases of any therapeutic failure.

2. I could conclude based on the results of the 3 successfully treated patients that the percutaneous transhepatic portal vein puncture and stent implantation in the cases of the rare early portal vein stricture is feasible and safe. This treatment can replace successfully surgical revision of the anastomosis and should be the first line treatment choice. Early diagnosis based on the CDUS findings and clinical signs should be established as soon as possible, and prompt treatment according to the adequate diagnosis have to be started.
3. Strictures of the inferior caval vein (IVC) are rare. Based on my results I concluded that early invasive pressure gradient measurements, morphological prove of strictures with diagnostic imaging. Having the right diagnosis treatment should be promptly started to avoid congestion of the renal a hepatic veins causing renal failure and liver function disturbances. In cases of early IVC strictures metallic stent implantation has a real benefit over balloon dilatation, therefore its use is recommended as a first choice from the treatment options, so retransplantation can be avoided.
4. Intrahepatic non-anastomotic bile duct strictures are usually treated with retransplantation. Surgical resection, endoscopic stent implantation is rarely a real therapeutic option, so percutaneous transhepatic drainage is the first line treatment modality in these cases. Application of metallic stents are controversial in any benign biliary stricture, because of the need for frequent reintervention. However, my results are promising in this indication, having long term symptom-free survival, and avoided liver retransplantation. Further investigations are needed to decide which patient benefits from stent implantation without long term patency problems and what is the reason for the frequent need for reintervention.

5. The diagnostic and therapeutic algorithms I prepared can serve as a valuable base for further workout taking into account further scientific innovations. This work should be done in our center by the liver transplantation team, including the interventional radiologist.

List of publications:

Connected to the study:

1. Doros A, Németh A, Deák AP, Hartmann E, Gerlei Z, Fazakas J, Kóbori L. Successful Treatment with a Covered Stent and 6-Year Follow-Up of Biliary Complication After Liver Transplantation.
Cardiovasc Intervent Radiol. 2009; ISSN:1432-086X (Electronic).
DOI 10.1007/s00270-009-9558-y

2. **Doros A**, Németh A, Hartmann E, Deák PÁ, Juharosi Gy, Lénárd Zs, Kozma V, Görög D, Gerlei Zs, Fehérvári I, Nemes B,. Kóbori L. Öntáguló fémstentek a májátültetés után kialakult intrahepaticus epeúti szűkületek kezelésében.
Magy Rad. 2009;83:8-13

3. Doros A, Nemes B, Fehérvári I, Görög D, Gerlei Zs, Németh A,Hartmann E, Deák PÁ, Fazakas J, Tóth Sz, Kóbori L. Percutan transhepaticus fémstent behelyezésével kezelt májkapuvéna-szűkületek májátültetés után.
Orv Hetil. 2009;150:1231-1234.

4. Doros A, Weszelits V, Puhl M, Fehérvári I, Alföldy F. Perkután vena portae embolisatio májreszekció előtt.
Magy Seb. 2003;56:39-44.

5. **Doros A**, Németh A, Hartmann E, Deák PÁ, Fehérvári I, Tóth Sz, Nemes B, Kóbori L. Ballonos tágítás és fémstent behelyezés a vena cava inferior májtátültetés után kialakult szűkületeiben.
Magy Rad. 2009;83:80-85.

6. Kóbori L, Németh T, Nagy P, Dallos G, Sótonyi P Jr, Fehérvári I, Nemes B, Görög D, Patonai A, Monostory K**, Doros A**, Sárváry E, Fazakas J, Gerlei Z, Benko T, Piros L, Járay J, De Jong KP. Experimental results and clinical impact of using autologous rectus fascia sheath for vascular replacement. Acta Vet Hung. 2008;56:411-420.

7. Nemes B, Polak W, Ther G, Hendriks H, Kóbori L, Porte RJ, Sárváry E, de Jong KP, **Doros A**, Gerlei Z, van den Berg AP, Fehérvári I, Görög D, Peeters PM, Járay J, Slooff MJ. Analysis of differences in outcome of two European liver transplant centers. Transpl Int. 2006;19:372-380.

8. Kóbori L, **Doros A**, Németh T, Fazakas J, Nemes B, Slooff MJ, Járay J, de Jong KP. The use of autologous rectus facia sheath for replacement of inferior caval vein defect in orthotopic liver transplantation.
Transpl Int. 2005;18:1376-1377.

9. Nemes B, Sárváry E, Sótonyi P, Gerlei Z, **Doros A**, Gálffy Z, Fehérvári I, Fazakas J, Járay J, Kóbori L. Factors in association with sepsis after liver transplantation: the Hungarian experience.
Transplant Proc. 2005;37:2227-2228.

10. V. Weszelits V, **Doros A**, Puhl M, Dabasi G, Görög D, Nemes B, Perner F. 3D CT angiography in patients before and after liver transplantation.
Transplant Proc. 2001;33:1372-1376.

11. Kóbori L, Máthé Z, Fazakas J, Gerlei Z, **Doros A**, Fehérvári I, Sárváry E, Hartmann E, Németh A, Mándli T, Tóth S, Szonyi L, Korponay Z, Kiss M, Görög D,
Járay J. A gyermekkori májátültetés sebészeti alapjai. Az élődonor-program első lépései Magyarországon.
Orv Hetil. 2008;149:1271-1275.

12. Nemes B, Zádori G, Hartmann E, Németh A, Fehérvári I, Görög D, Máthé Z, Dávid
A, Jakab K, Sárváry E, Piros L, Tóth S, Fazakas J, Gerlei Z, Járay J**, Doros A**. Epeúti szövődmények májtranszplantáció után.
Orv Hetil. 2008;149:963-973.

13. Németh A, **Doros A**, Hartmann E, Járay J. Élő donoros májátültetés recipienseinek pre- és posztoperatív képalkotó vizsgálatai.
Orv Hetil. 2008;149:69-76.

14. Hartmann E, Németh A, **Doros A**, Balázs G, Járay J. A képalkotó módszerek szerepe az élő donoros májtranszplantáció donorjelöltjeinek pre- és intraoperatív vizsgálatában, valamint posztoperatív követésében Magyarországon.
Orv Hetil. 2008;149:13-18.

15. Görög D, Fehérvári I, **Doros A**, Nemes B, Máthé Z, Kóbori L, Járay J. Subcapsularis haematoma és graftruptura májátültetés után.
Magy Seb. 2008;61:230-233.

16. Nemes B, Sárváry E, Gerlei Z, Fazakas J, **Doros A**, Németh A, Görög D, Fehérvári I, Máthé Z, Gálffy Z, Pár A, Schuller J, Telegdy L, Fehér J, Lotz G, Schaff Z, Nagy P, Járay J, Lengyel G. Hepatitis C-vírus kiújulása májátültetés után.
Orv Hetil. 2007;148:1971-1979.

17. Nemes B, Kóbori L, Fehérvári I, Fazakas J, Gerlei Z, Ther G, Görög D, Perner
F, Doros A, Sárváry E, Járay J. Hagyományos és piggyback technikával végzett májátültetések eredményeinek összehasonlítása.
Magy Seb. 2005;58:155-161.

18. Nemes B, Kóbori L, Gálffy Z, Lengyel G, **Doros A**, Sárváry E, Perner F, Schaff
Z, Fazakas J, Szalay F, Féher J, Járay J. A májátültetés szövődményeit és túlélési eredményeit befolyásoló tényezők Magyarországon.
Orv Hetil. 2005;146:1567-1574

Not connected to the study:

1.Doros A, Weszelits V, Puhl M, Rusz A, Jansen J. Transzplantált vesék ureterszűkületeinek kezelése invazív radiológiai módszerekkel.
Magy Rad. 2003;77: 68-72

2.Doros A, Viczena P. A nyaki erek ultrahang vizsgálatának jelene és várható jövõje. Honvédorvos Bp, 1996;48:1-12

3. Kóbori L, Nagy P, Máthé Z, Hartmann E, **Doros A**, Paku S, Dezso K, Sápi Z. Malignant peripheral nerve sheath tumor of the liver: a case report.
Pathol Oncol Res. 2008;14:329-332.

4. Fazakas J, Tóth S, Füle B, Smudla A, Mándli T, Radnai M, **Doros A**, Nemes B, Kóbori L. Epidural anesthesia? No of course.
Transplant Proc. 2008;40:1216-1217

5. Langer RM, Máthé Z, **Doros A**, Máthé ZS, Weszelits V, Filó A, Bucher P, Morel P, Berney T, Járay J. Successful islet after kidney transplantations in a distance over 1000 kilometres: Preliminary results of the Budapest-Geneva collaboration.
Transplant Proc. 2004;36:3113-3115.

6. Németh A, **Doros A**, Hartmann E, Weszelits V, Dabasi G, Langer Rt, Máthé Z, Járay J. A hasnyálmirigy-átültetés napjainkban: indikáció, műtéti technika, szövődmények, képalkotó vizsgálatok és eredmények.
Magy Rad. 2007;81: 182-194

7. Gerlei Zs, Gálffy Zs, Varga M, **Doros A**, Remport Á, Fazakas J, Ther G, Járay J
A SE Transzplantációs és Sebészeti Klinikán 2003-ban területen szerzett pneumonia miatt kezelt vesetranszplantált betegek retrospektív vizsgálata
Infekt Klin Mikrob. 2005;12: 13-17

8. Dévai T, Pálinszki A, Balázs Gy, **Doros A**: Új minőségfejlesztési módszer a magyar egészségügyben-Six Sigma a radiológiában.
Magy Rad. 2001;75:127-131

9. Glasz T, Rusz A, **Doros A**, Schaff Zs: Papilláris sejtes veserák.
Orv Hetil 2001;142: 1745-1747