The importance of biological grafts in the management of infrarenal prosthetic graft infections. Establish and operate a vascular homograft bank

Doctoral Theses

Dr. Bíró Gábor

Semmelweis University
Doctoral School of Clinical Sciences

Supervisor:	Dr. Nemes Attila D.Sc.
Official reviwers:	Dr. Vallus Gábor Ph.D. Dr. Hütt Tivadar Ph.D.
President of the final exam comitte:	Dr. Perner Ferenc D.Sc
Members of the final exam comitte:	Dr. Ludvig Endre Ph.D. Dr. Menyhei Gábor Ph.D.

Budapest
2011

Introduction

The infrarenal prosthetic graft infection continuos to be a major challenge in vascular surgery, and is influenced by different factors. The management of infected prosthetic graft is associated with high morbidity and mortality rates(30-50%). The generally followed strategy were in the 80's graft removal, aortic ligature and extra-anatomic bypass, but the extraanatomical bypass has a low patency rate and associated with 30% amputation rate. Also occurred aortic stump bleeding, with lethal outcome, and reinfection is possible in the inguinal plane either after femoropopliteal or aortofemoral reconstructions. The in situ strategy has improved the results. Different treatment options are silver or antibiotics impregnated grafts, homograft vessels, and the autologous deep vein implantation. The complete, long-term eradication of the infection was reported in case of deep vein use, but the other materials are offering also low reinfection rates. Homograft arteries are reported as an option to deep vein implantation. The reported series are different regarding the number of emergency cases, aortoduodenal fistulas, septic bleeding.

The cryopreserved homografts offer easier and more reliable logistics and the short and longterm results are better comparing with the fresh homografts. The comparison between homograft and deep vein implantation is on one issue is valid, namely how far the eradication of the infection is possible, even in the late follow up period, among patients who survived the serious septic condition and operation. The publications are paying less attention the involved bacterias. In principle the staphylococcus infections play a leading role with 45-50% incidence. In recent publications MRSA infections also mentioned as a complicated

infection. Gram-negativ bacterias are listed in many publications, but they have no special attention in the evaluation of the results.

Aims of the study

1. Establishing and operating a homograft vessel bank
2. Evaluation of the implantation of homograft vessels in the management of aortofemoral prosthetic graft infections. Comparison with the autologous deep vein implantation.
3. Determining the bacteriological spectrum and evaluation its impact on the morbidity and mortality
4. Determining of a management strategy in the treatment of aorto-iliaco femoral prosthetic graft infections, focusing on the role of cryopreserved homograft.

Methods

Homograft bank

Procurement and storing of cryopreseved homografts the following items, conditions and services are necessary

1. Appliances for deep freezing and storing
2. Tissue donor management and selection
3. Graft removal from cadaver and croypreservation processes
4. On call duty service for graft removal
5. Data management
6. Financing of the functioning system

Appliances for deep freezing and storing were purchased in 1997 for the Department of Cardiovascular Surgery, Semmelweis University. Beside these items a contact were established to join to the functioning organ removal service operated by the Department of Transplantation Surgery. The evaluation and selection process of the donors for organ transplantation were fulfilled the conditions for vessel removal.
An on call duty system was set up for operative removal, graft procurement and freezed storing in 24 hours after removal.

Lavage treatment

Between 01.01.1983 and 31.12.1990. 42 patients were investigated and the early and late results were evaluated in case of infected prosthetic grafts using local washing-suction(lavage) treatment. The early and late investigation were performed in more studies. 29 patients were involved in the late follow up control.

The treatment options for aortofemoral prosthetic graft infections were changed after starting the homograft bank, and the first replacement with deep vein in.

Homograft and deep vein implantations

1996.01.01 to 2008.12.31. 33 patients were managed with aortoiliac graft infection. 19 patients underwent a reconstruction with use of cryopreserved homografts, 14 patients had a replacement of the infected prosthetic graft with autologous femoral deep vein. Homografts were removed from heart beating donors and procured by the previously mentioned method.

Deep veins were removed, after evaluating the anamnestic data and previous Duplex ultrasound mapping, during the operation of the infected prosthetic graft. The selection of the type of operation were based on the emergency condition at the admission, the risk factors and cardiopulmonary status, which was assessed by echocardiographic evaluation of the cardiac ejection fraction and, lung function tests. The homograft implantation were preferred, if the cardiac ejection fraction was under 50% and the patient had 2 or more risk factors The clinical presentation was inguinal purulent discharge in 79%, septic pseudoaneurysm in 8%, septic bleeding in 17,6% and aortoduodenal fistula in 20,5%. The diagnosis were based on CT scan in 29 cases. The mean age of the patients was 63.5±4 years, for homograft group(HG) 67.01±3.15 years, for deep vein group(DV) 58.37±3.8years, male/female ratio 23 men, 10 women. The interval between implantation of synthetic graft and the appearance of infection was 47.78±19.9 months (HG:42.82±20.7 months, DV:55.22±19 months). Aspirate of wound cultures were performed before the operations and during the reconstructions from the deep tissue layers and prosthetic grafts. Organisms included most often Staphylococcus aureus, but pluribacterial infections were in 15 patients. 45% of the infections were caused by Gram-negativ bacterias.

22 homografts were implanted; all but 4 were artery segments. 1 thoracic aortic segment, 6 aortoiliac bifurcated segments, 5 iliofemoral artery segments, 8 superficial femoral artery segments and 4 deep vein segments were used. Blood group compatibility was feasible in 7 cases, matching of blood group between recipient and donor in 12 patients was not attempted.

14 patients were operated on involving 20 deep veins. Adequate length of the femoral vein were removed and GSV was also applied in 1 patient. The complete removal of the infected proshtetic graft is always performed.

Aortoduodenal fistula

Over a twenty-year period (1989-2009), 48 patients (33 men and 15 women, mean age: 64 years) were treated for secondary aortoenteric fistulas (SAEF). Most of the patients presented with symptoms of gastrointestinal bleeding (42 cases), or of serious septicaemia and general septic conditions (19 cases). Twenty-eight patients (58.3%) required an emergency procedure and were admitted with an unstable hemodynamic status. Repairs were accomplished by graft removal and an axillobifemoral bypass (n=11), in situ reconstruction with a silver-impregnated prosthetic replacement (n=21), a Dacron graft replacement (n=7), a cryopreserved homograft replacement (n=8) or an in situ deep vein replacement (n=2).The closure of the duoudenum and separation with omentum always was performed. The application of Dacron grafts was typical in the first decade in extraanatomic position, and we used silver impregnated grafts (InterGuard Silver InterVascular LaCiotat, France) in 23 cases in the second study period.

Routine follow up included clinical examination and laboratory tests at 3-month intervals during the first year, and clinical examinations yearly thereafter. In case of suspicion of repeat infection duplex scanning was performed. If ultrasound proved fluid collection around the graft late CT or aortography was performed.

The patient records were retrospectively evaluated. The statistical analysis was performed by SPSS 13.0 software, the long term follow up results were evaluated by Kaplan-Meier analysis, and significance was assessed

by Student's t-test and log-rank test. Confidence intervals are calculated according to the efficient-score method. A p value <0.05 was considered significant.

Results

Homograft bank

After the first vessel removal on 19.05.1997 together with the organ transplant team, we took part 68 multi organ harvest procedure. Male female ratio of the donors were 46 men and 22 women, mean age is 37.8(16-62)years. The serologic evaluation revealed no HIV, HB, HC and syphilitic infections. CMV test were negativ in 15(22%) patients. 427 vessels were harvested and prepared for croypreservation. After the bacteriological tests 407 grafts were evaluated as available for banking. The artery/vein ratio was 4:3 among the grafts. Arterial grafts were 21 thoracic aorta, 23 bifurcated abdominal aorta, 15 iliacal artery 19 iliaco-politeal artery and 78 femoro-popliteal artery segments The most often removed vein was the greater saphenous vein (115), and as a large caliber vein, 90 deep femoral vein also were procured.

During eleven years the Department of Cardiovascular Surgery, Semmelweis University implanted 226 grafts, and according to our goal, 12 grafts were transferred for other institutions if the indication existed for homograft implantation. The homografts usage involved 4 basic indications Grafts were mostly implanted during infrainguinal reconstructions when the GSV is not available due to previous vascular, cardiac surgical procedure, or varicectomy or poor caliber. 106 patients

were operated with 123 grafts, among them 76 GSV, 4 deep veins, and 43 arterial segments were implanted in infrapopliteal reconstructions.

In management of prosthetic graft infections 51 patiens were treated with 64 implanted grafts. The infection occurred either after infrainguinal or after aorto-iliaco-femoral operations. The proportion of large caliber homografts is higher in this group, 40 arteries, 24 veins were implanted. 19 patients were treated with aortoiliacal graft infections and 31 patients received homograft for the management of infrainguinal prosthetic graft infections.

Further indication of homograft usage is the treatment of infected arteriovenous fistulas for hemodialysis treatment. In our practice 8 patients underwent homograft implantaiton for this purpose.

The cardiac surgical application involved of 11 GSV implantation as a coronary bypass, and 2 valve replacement for septic xenograft.

Early results of the lavage treatment

29 patients were treated and a healing of the infection achieved in 20 patients, in 9 patients the treatment failed, and a repeated treatment was also unsuccessful in 3 patients. During the lavage treatment 2 grafts occluded without critical leg ischemia. Four failed patients underwent graft removal and extraanatomic bypass implantations. The other 5 patients with unsuccessful lavage treatment due to the poor distal runoff underwent only graft removal and major amputation. The lavage treatment and the following operations were not associated with lethal outcome.(Table 1).

Table 1: Early results of the lavage treatment

Unsuccesful treatment	31%
Amputation	17%
Lethal outcome	0%

Aspirate of wound cultures revealed in 16 cases Staphylococcus aureus, in 7 cases different types of Streptococcus, in 4 cases Proteus and in 2 cases Pseudomonas aeruginosa infections. The control cultures from the tubes verified in failed cases always retained infection, mostly Proteus and Pseudomonas were involved, and new Staphylococcus infections were also presented. 6 from the 7 non anastomotic infection healed, but 14 from the 22 anastomotic infections were succesful.

Late results of the lavage treatment

The follow up period is 5.2(2.8-9.2)years. 2 patients died, no report was available in 4 patients. The mortality was infection related due the a repated graft infection. 6 patients underwent major amputation during the follow up, 4 of them were caused by the repaeted prosthetic infections. In summary 40% of the patients have a functioning non infected graft, 60% of the treatment failed for the late follow up period. The primary cultures verified Staphylococcus aureus or Streptocuccus pyogenes infections among the 17 successfully treated patients. The 25 failed cases presented 21 Gram-negativ bacterial colonisation.

Results of the homograft and deep vein replacements

Bacteriology

Organisms included Staphylococcus aureus in 15 patients (45%), MRSA in 6 patients (18%), Klebsiella in 7 patients (21%), Pseudomonas, and Proteus in 6 patients each(18%), Escherichia coli and Salmonella in 2 patients each(6%), and Enterococcus faecalis, Streptococcus Pyogenes, Streptococcus agalactiae one patient each. 11 patients had pluribacterial infections.

Early results

24 homografts for 19 patients were implanted; all but 4 were artery segments. 1 thoracic aortic segment, 6 aortoiliac bifurcated segments, 5 iliofemoral artery segments, 8 superficial femoral artery segments and 4 deep vein segments were used. Blood group compatibility was feasible in 7 cases, matching of blood group between recipient and donor in 12 patients was not attempted. 14 patients were operated on involving 20 deep veins. Adequate length of the femoral vein were removed and GSV was also applied in 1 patient. Table 2. presents the detailed operative methods and the position if the infected grafts.

Table 2: Operative strategy in case of aorto-iliacofemoral prosthetic graft infection.

	Primary operations		Management of infection	
Deep vein Gr.				
	Aortobifemoral bypass	11	Aortobifemoral bypass	6
			Aortofemoral bypass	3
			Iliofemoral bypass	1
			Iliofemoral high crossover bypass*	1
	Aortofemoral bypass	2	Aortofemoral bypass	2
	Aortoiliac endarterectomy with prosthetic patch	1	Iliofemoral crossover bypass	1
Homograft Gr.				
	Aorto-aortic tube graft	3	Aorto-aortic tube graft	1
			Aortobiiliac bypass	2
	Aortobifemoral bypass	10	Aortobifemoral bypass	4
			Aortofemoral bypass	4
			Aortobifemoral bypass with distal bifurcation	2
	Iliofemoral bypass	2	Aortofemoral bypass	2
	Iliofemoral crossover bypass	3	Iliofemoral crossover bypass	3
	Aortoiliac endarterectomy with prosthetic patch	1	Iliofemoralis bypass	1

Recurrent, septic hemorrhage in the postoperative period was observed in 5 patients, twice in 2 patients. Four bleeding occurred in HG one in DV group. The bleeding occurred from the aorta to graft anastomosis in 3 patients, and from inguinal anastomosis in two patients. No graft rupture was observed. All 5 patients underwent an emergency operation, aortic

ligature and axillobifemoral bypass was performed in one patient, and in the other 4 cases the bleeding anastomoses were re-sutured and covered with muscular flap in the groin and omental patch at the aortic anastomosis to avoid further bleeding. Four patients died after the reoperation, one further lethal outcome were caused by acute coronary syndrome in DV group. Overall, 4 patients died from the homograft group (21%), and two in the deep vein group(14.3%) within 30 days. The difference is not significant, p=0.126. Among the 6 deceased patients 5 were presented as emergency case with aortoduodenal fistula, the sixth with acut septic bleeding from the groin. All but one deceased patients had Gram-negativ bacteria in cultures and pluribacterial infections. The survivors presented less Gram-negative infections. In HG group 5 patients from 15, in DV group 5 from 12 suffered from Gram-negativ infection.

In the aortoduodenal fistula group early perioperative (<30 day) mortality was 45.8%. There was a significant difference in the mortality rates between patients who had an emergency procedure (59.2%) and patients who underwent urgent (38.0%) operations (P<0.04).(Table 3.)

Table 3. Early mortality of operative treatment due to aortoenteric fistulas

	No.	Early death	% Early death
Type			
Emergency	28	16	57.1%
Urgent	20	8	40.0%
Technic			
In situ	35	16	45.7%
Extraanatomic	11	6	54.6%
Explantation only	2	2	
Graft removal			
Complete	35	18	51.%
Partial	13	6	46.2%
Applied graft material			
Silver impregnated	23	8	34.7%
Dacron	13	6	46.1%
Homograft	8	6	75%
Deep vein	2	2	100%

Late results

The mean duration of follow up was 36.87±20.25 (range 2-150). All but one the 27 discharged patients had sustained or improved walking distance; two patients had to wear compression elastic stockings. During the follow-up period, data were collected from 33 patients, the homograft group was followed up for 17.2 months, and the deep vein group was followed up for 56.9 months. This remarkable difference in follow up period between the two groups is explained by two facts; our homograft bank is established in 1998, and the first implantation for aortoiliac infection was performed at end of that year. Replacement with autologous

deep vein was performed from the year 1994, and 3 patients still alive from this peirod. During the follow up period 4 patients died (2 in each groups) unrelated to the reconstructions. The causes of death were multi organ failure, gastrointestinal hemorrhage, and myocardial infarction in one patient each , unknown in one. The 3-year cumulative survival is 79% (CI:0.49-0.94) in the deep vein group, and 71% (CI:0.48-0.88) in the homograft group (Figure 1). The difference is not significant p=0.66.

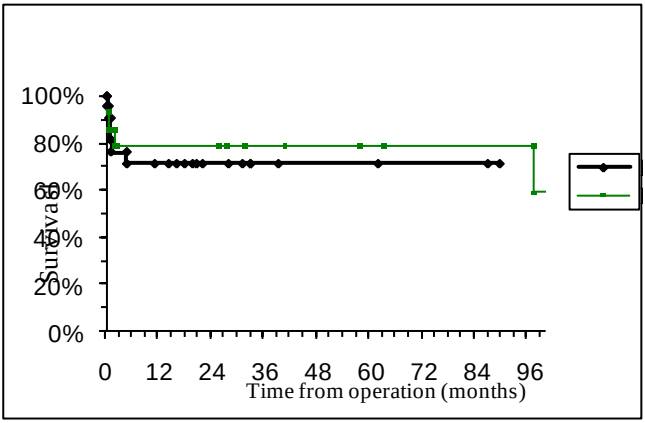

Figure 1: Kaplan-Meier estimates of overall patient survival in patients treated with homograft (HG), and deep vein(DV)

Graft patency after 3 years were 87% (CI:0.61-0.98) in HG group and, 90% (CI:0.58-0.99) in DV group. The difference is statistically non significant p=0.55 (Figure 2.)

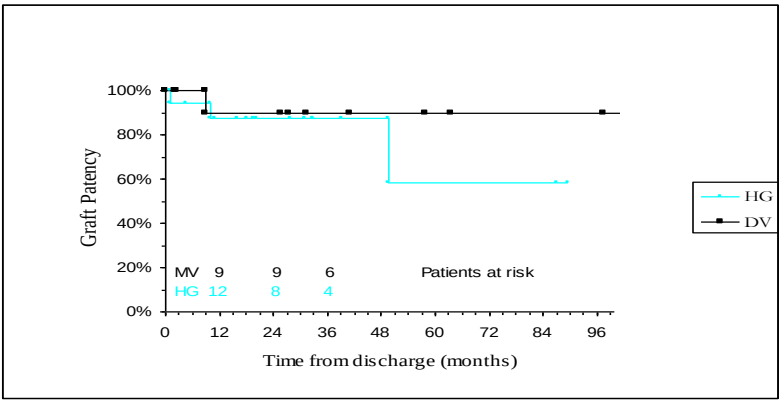

.

Figure 2. Kaplan Meier estimates of primary graft patency rates in survived patients treated with homograft (HG), and deep vein(DV

Three patients in the HG group were treated for recurrent inguinal infection 2, 5 and 6 months later. Staphylococcus infection was found twice and no bacterial infection was found in the other case. None of the patients in DV group developed recurrent infection.Graft exposure and local debridemant were performed to eliminate the infection Kaplan-Meier analysis revealed 82% (CI:0.56-0.92) freedom from infection in the homograft group 36 months later (Figure 3.) The difference is not significant (P=0.158). No aneurysmal dilatation was observed in any groups.

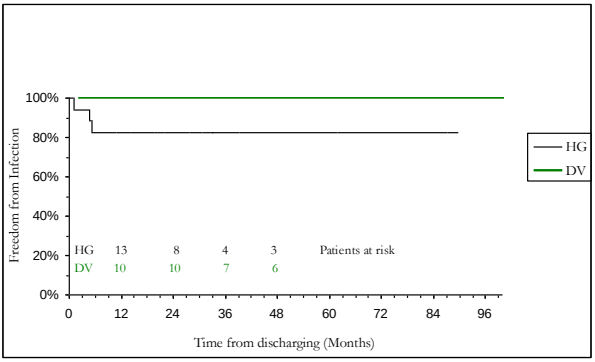

Figure 3: Kaplan-Meier estimates of freedom from infection after discharging in survived patients treated with homograft (HG), and deep vein(DV)

The average follow-up period in aortoduodenal fistula group was 48.6±16 months. There were eight late deaths; three of which were related to the SAEF treatment. The cumulative mortality rate was 34% at three years. Six late graft infection occurred, three of them were associated with lethal outcome, and were evaluated as related with the management of aortoduodenal fistula. The late survival of patients in the urgently and emergently operated on groups was also compared and significant difference was observed Fig.4

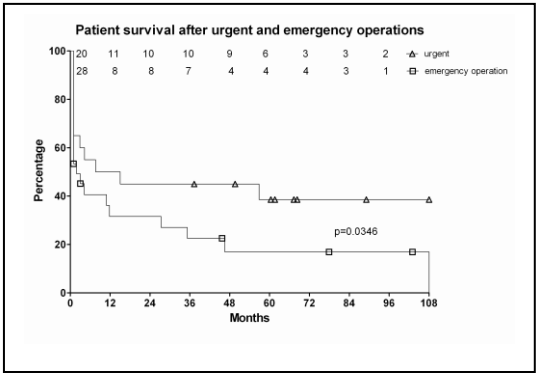

Fig.4. Late survival of the urgently and emergently operated groups after secondary aortoenteric fistula repair (life table method) at 5 years urgent:38.7% emergently:18.2% SE<10%

Other factors, as extent of graft removal, the applied graft material, applied operative technic had no influence on the late survival.

Kaplan-Meier analysis estimated an 80.6% freedom from infection at three and five years in the entire study group (SE<10%). We found a slightly better infection control (87.5% silver-graft compared with 66.7% dacron graft) comparing the subgroup of patients who were managed with silver-impregnated or dacron grafts (Fig5.), and no difference in infection control among subgroups of complete or partial graft removal.

Fig.5. Kaplan Meier analysis of freedom from reinfection using silver-impregnated and dacron grafts. Three-year results are 87.5% and 66.7%, respectively. SE<10%

Conclusions

1. The homograft bank is established, which preserves and produces cryopreserved homografts and guarantees a sufficient supply for the national vascular surgical services.
2. The lavage treatment in the management of aortofemoral prosthetic graft infections has a limited role. This method is offered for early infections and in case of non Gram-negativ bacterial colonization. The lavage is a choice for high risk patients but a long term success is not guaranteed.
3. The use of crypreserved homografts achieves long term infect free period for aortofemoral proshtetic graft infections, and this result is comparable with the excellent results of the autologus deep vein implantation.
4. In case of emergency conditions, and/or if the aortoiliacal graft infection is complicated with aortoduodenal fistula the silver impregnated graft implantation is available to save the patients life. In particular cases is possible the partial resection of the involved graft.
5. The presence of Gram-negativ bacterias means an increased risk in mortality, this effect is remarkable in the early postoperativ period and independent from the applied graft material.
6. I offer the following management strategy for aortofemoral prosthetic graft infections.

Low risk patient	Graft explantation, in situ deep vein,
Low risk patient, autologous deep vein not available	Graft explantation insitu homograft, or silver impregnated graft ,
Medium risk patient	Graft explantation insitu homograft, or silver impregnated graft,
High risk patient, partial involvment of the graft	Partial graft explantation, impregated graft,
High risk patient, complete graft infection	Graftpreservation, long term antibiotic treatment

Publications in recent issue

1. Entz L., Bíró G. , Nemes A. Septicus érprotézis öblitö szivó (lavage) kezelése Orvosi Hetilap, **131**. 23. 1255-1257., 1990
2. Nemes A., Bíró G. , Entz L. Lavagebehandlung der infizierten Gefäßprothese Steinkopff Verlag, Wundinfektionen in der Gefäßchirurgie, 1991 63-66.
3. Acsády Gy., Entz L., Bíró G., Hüttl K., Nemes A. Erfahrungen mit der rekonstruktiven Chirurgie der tiefen Venen Vasa, 1993 42. suppl. 20-22.
4. Bíró G., Entz L., Nemes B., Gálfi I. Alsóvégtagi mélyvénák használata érsebészeti protézis gennyedés megoldására Magyar Sebészet, **51**. 293-296. 1998

5. Bíró G., Szabó A., Szeberin Z., Nemes A.Homograft beültetéssel végzett artériás rekonstrukciók Magyar Sebészet, 2001 Dec **54.** 63-67.
6. Szeberin Z., Bíró G., Szabó G., Százados M., Nemes B., Dzsinich Cs. Aortobifemoralis graft készítése vena femoralis superficialisból Érbetegségek 14(1), 7-11,2007
7. G.Bíró, Z.Szeberin, A.Nemes, Gy.Acsády Cryopreserved homograft and deep vein replacement for infrarenal aortofemoral and iliacofemoral graft infection: Early and late results. J of Cardiovascular Surgery, 51, 2010 Apr;52(2):169-76
8. G. Bíró, G. Szabó, M. Fehérvári, Z. Münch, Z. Szeberin, Gy. Acsády Late outcome following open surgical management of secondary aortoenteric fistula
   Langenbeck's Archives of Surgery 2011 DOI: 10.1007/s00423-011-0807-6

Other publications

1. Bíró G., Acsády Gy.Spontán aorto-cavalis fistula: a hasi aorta aneurysma ritka szövődménye Magyar Sebészet, 45. 89-94., 1992
2. Bíró G., Nyikos Gy.A visceralis verőerek megbetegedései; a sebészetileg kezelhetõ hypertonia Háziorvosi Szemle, 12-14., 1997
3. Nemes A., Pintér L., Hüttl K., Bíró G., Acsády Gy. Proximal bleeding control obtained by a balloon catheter in the surgical repair of a left supraclavicular traumatic arteriovenous fistula J Vasc Surg, 25. 587-590, 1997

4. Szeberin Z. Bíró G., Sótonyi P., Soós P., Százados M., Árkossy O., Berta K., Acsády Gy. Proximalis radio-cephalikus autológ fisztulák szerepe a emodialízis-kezelés biztosításában Magyar Sebészet 59, 421-428, 2006
5. Bíró G., Szeberin Z., Hethéssy J. A könyöktáji fisztula műtét helye és hosszú távú eredménye a hemodializis kezelésben Érbetegségek 14(1), 21-25,2007
6. Szeberin Z, Bíró G, Sótonyi P, Soós P, Százados M, Árkossy O, Berta K, Acsády G. The role of autologous antebrachial arteriovenous fistula in the strategy of access planning for chronic uremic patients on hemodialysis.
Minerva Urol Nefrol. 2007 Sep;59(3):231-6.
7. Szeberin Z, Firneisz G, Bíró G, Szabó GV, Sótonyi P, Windisch M, Krepuska M, Sípos F, Mihály E, Acsády G. B tipusú aortadissectio sebészi kezelése kokaint használó beteg esetén Orv Hetil. 2009 Jan 19;150(3):129-31
8. Szabolcs Z, Veres G, Hüttl T, Bíró G, Tóth A, Szeberin Z, Windisch M, Acsády G. Egyszerű sebészi módszer az aorta ascendensben elhelyezkedő nagy, lebegő thrombus eltávolítására. Orv Hetil 2007 Feb;148(8):363-366
9. Z.Szeberin, M.Fehérvari, M.Krepuska, A.Apor, E.Rimely, H.Sarkadi, G.Bíró P.Sótonyi, G.Széplaki, Z Szabolcs, Z Prohászka, L. Kalabay, Gy. Acsády Fetuin-A serum levels in patients with aortic aneurysms of Marfan syndrome and atherosclerosis
Eur J Clin Invest 2011; 41 (2): 176–182